

# Voxel-based morphometry reveals reduced grey matter volume in the temporal cortex of developmental prosopagnosics

Lúcia Garrido,<sup>1</sup> Nicholas Furl,<sup>2</sup> Bogdan Draganski,<sup>3</sup> Nikolaus Weiskopf,<sup>2</sup> John Stevens,<sup>4</sup> Geoffrey Chern-Yee Tan,<sup>2</sup> Jon Driver,<sup>1,2</sup> Ray J. Dolan<sup>2</sup> and Bradley Duchaine<sup>1</sup>

1 UCL Institute of Cognitive Neuroscience, University College London, London WC1N 3AR, UK

2 UCL Wellcome Trust Centre for Neuroimaging, University College London, London WC1N 3BG, UK

3 Max Planck Institute for Human Cognitive and Brain Sciences, Leipzig 04103, Germany

4 UCL Institute of Neurology, University College London, London WC1N 3BG, UK

Correspondence to: Lúcia Garrido,  
Institute of Cognitive Neuroscience,  
Alexandra House,  
17 Queen Square,  
London WC1N 3AR,  
UK  
E-mail: m.garrido@ucl.ac.uk

Individuals with developmental prosopagnosia exhibit severe and lasting difficulties in recognizing faces despite the absence of apparent brain abnormalities. We used voxel-based morphometry to investigate whether developmental prosopagnosics show subtle neuroanatomical differences from controls. An analysis based on segmentation of T1-weighted images from 17 developmental prosopagnosics and 18 matched controls revealed that they had reduced grey matter volume in the right anterior inferior temporal lobe and in the superior temporal sulcus/middle temporal gyrus bilaterally. In addition, a voxel-based morphometry analysis based on the segmentation of magnetization transfer parameter maps showed that developmental prosopagnosics also had reduced grey matter volume in the right middle fusiform gyrus and the inferior temporal gyrus. Multiple regression analyses relating three distinct behavioural component scores, derived from a principal component analysis, to grey matter volume revealed an association between a component related to facial identity and grey matter volume in the left superior temporal sulcus/middle temporal gyrus plus the right middle fusiform gyrus/inferior temporal gyrus. Grey matter volume in the lateral occipital cortex was associated with component scores related to object recognition tasks. Our results demonstrate that developmental prosopagnosics have reduced grey matter volume in several regions known to respond selectively to faces and provide new evidence that integrity of these areas relates to face recognition ability.

**Keywords:** developmental prosopagnosia; voxel-based morphometry; face recognition; object recognition; perception; temporal cortex

**Abbreviations:** CFMT = Cambridge Face Memory Test; ITG = inferior temporal gyrus; MDEFT = modified driven equilibrium fourier transform; MT = magnetization transfer; MTG = middle temporal gyrus; STS = superior temporal sulcus; SVC = small volume correction; VBM = voxel-based morphometry

## Introduction

The study of patients who have lost their ability to recognize faces following brain injury (acquired prosopagnosia) has led to significant insights into the cognitive operations and neural mechanisms involved in face processing (Bodamer, 1947; Damasio *et al.*, 1982; Bruce and Young, 1986; De Renzi, 1986; Farah *et al.*, 1995; Wada and Yamamoto, 2001; Barton *et al.*, 2002; Rossion *et al.* 2003). But some people with no history of neurological damage can also experience severe problems recognizing faces (Bornstein, 1963; McConachie, 1976). This condition, called developmental prosopagnosia, has received increased attention in the past decade (e.g. Kress and Daum, 2003; Behrmann and Avidan, 2005; Duchaine and Nakayama, 2006a). Because the behavioural deficits in developmental prosopagnosia are often selective, it provides a promising avenue to explore the cognitive basis of face processing and visual recognition more generally (e.g. Duchaine *et al.*, 2006; Bentin *et al.*, 2007; Humphreys *et al.*, 2007). Studies of developmental prosopagnosia may also contribute to our understanding of brain areas involved in face recognition. Case studies of patients with acquired prosopagnosia have been essential for this issue (e.g. Wada and Yamamoto, 2001; Rossion *et al.*, 2003; Bouvier and Engel, 2006; Barton, 2008), and identification of the neural basis of developmental prosopagnosia could provide further evidence about the contribution of different regions in the face processing network.

A variety of methods have demonstrated that regions of the posterior fusiform gyrus, the inferior lateral occipital cortex and the posterior superior temporal sulcus (STS) are involved in face processing (e.g. Sergent *et al.*, 1992; Allison *et al.*, 1994a, 1999; Kanwisher *et al.*, 1997; Rossion *et al.*, 2003; Grill-Spector *et al.*, 2004; Barton, 2008; Pitcher *et al.*, 2009). An influential account by Haxby *et al.* (2000) described these regions as forming a 'core system' for face processing, while also suggesting that regions of the fusiform gyrus may be especially important for processing facial identity. Neuropsychological and functional magnetic resonance imaging (fMRI) studies are consistent with this claim (e.g. Wada and Yamamoto, 2001; Winston *et al.*, 2004; Rotshtein *et al.*, 2005; Yovel and Kanwisher, 2005; Barton, 2008), but functional neuroimaging studies with small numbers of developmental prosopagnosics have to date failed to show consistently atypical responses to faces in the fusiform gyrus. Healthy individuals typically show a fusiform face area yielding higher activation to faces than objects in the fusiform gyrus (Kanwisher *et al.*, 2007), but the fusiform face area appears to be normal in many developmental prosopagnosics tested to date (Hasson *et al.*, 2003; Avidan *et al.*, 2005; Williams *et al.*, 2007; but see Bentin *et al.*, 2007; Van den Stock *et al.*, 2008; Minnebusch *et al.*, 2009). Functional neuroimaging studies of normal face processing have also shown that repeating the same face can lead to a decrease in the fMRI response (repetition suppression—Grill-Spector and Malach, 2001) in the fusiform face area/posterior fusiform gyrus (e.g. Winston *et al.*, 2004; Rotshtein *et al.*, 2005; Yovel and Kanwisher, 2005). Although one developmental prosopagnosic did not show repetition suppression in the fusiform face area when the same unfamiliar face was repeated (Williams *et al.*, 2007), four developmental

prosopagnosics have been reported to show normal repetition suppression for faces (Avidan *et al.*, 2005).

Recent work has suggested that a region in the anterior inferior temporal lobe may also be important for face recognition. Like the 'core' areas, it also shows larger responses to faces than non-face objects (Allison *et al.*, 1994b, 1999; Tsao *et al.*, 2008; Rajimehr *et al.*, 2009), and some evidence suggests that it is involved in face identification (Sergent *et al.*, 1992; Kriegeskorte *et al.*, 2007). Kriegeskorte *et al.* (2007) reported that the anterior inferior temporal lobe, but not the fusiform face area, was involved in differentiating between two faces. Importantly, a recent MRI volumetric analysis study showed that six developmental prosopagnosics had smaller anterior fusiform gyri than controls (Behrmann *et al.*, 2007), again suggesting an important role of this anterior inferior temporal region for face recognition. But like the functional neuroimaging studies of developmental prosopagnosia discussed above, this study had a relatively small sample of developmental prosopagnosics. Moreover, it only examined temporal lobe structures.

The present study sought to determine the structural anatomical correlates of developmental prosopagnosia, using MRI to investigate whether there are any regionally specific differences in brain grey matter in a group of 17 developmental prosopagnosics compared with matched controls. Unlike the two previous studies using structural imaging in developmental prosopagnosia (Bentin *et al.*, 1999; Behrmann *et al.* 2007), we examined the whole brain and used an unbiased and automatic method for structural analysis. Voxel-based morphometry (VBM) (Ashburner and Friston, 2000; Good *et al.* 2001; for reviews see Ashburner *et al.*, 2003; Mechelli *et al.*, 2005; Ashburner, in press) has been extensively used to investigate morphological changes associated with neurological and psychiatric conditions (e.g. Kubicki *et al.*, 2002; Karas *et al.*, 2004), specific cognitive impairments (e.g. Silani *et al.*, 2005; Hyde *et al.*, 2006), and particularly well-developed or trained abilities in healthy individuals (e.g. Maguire *et al.* 2000; Draganski *et al.*, 2004; Mechelli *et al.*, 2004). We predicted that developmental prosopagnosics would exhibit structural abnormalities in regions that show face-selective responses, namely in regions comprising the 'core system' for face processing (Haxby *et al.*, 2000) plus the anterior inferior temporal lobe (Allison *et al.*, 1994b; Tsao *et al.*, 2008). With the further aim of understanding how any such structural abnormalities might relate to behavioural deficits, we also implemented an extensive battery of face and object processing tasks, analysed performance on all these for any principal components, and then investigated with VBM the structural correlates of these behavioural components.

## Materials and methods

### Participants

We tested 20 individuals with face recognition difficulties and 19 control participants. Some controls were friends of the developmental prosopagnosics, and others were recruited from a departmental subject pool. We excluded from the analysis all individuals who had any history of neurological conditions or visual impairments that could

explain face recognition difficulties or interfere with the procedure. Data from three developmental prosopagnosics and one control were excluded from the analysis (one excluded developmental prosopagnosic has epilepsy, one may have suffered brain damage after birth, and one had strabismus; one control appeared to have mild microcephaly). The final sample thus comprised 17 developmental prosopagnosics (11 females) and 18 controls (11 females). All reported being right-handed. The two groups were matched for age and IQ. The mean age for developmental prosopagnosics was 30.94 years ( $SD=7.54$ , range 20–46) and for controls it was 28.94 ( $SD=5.70$ , range 23–43), which did not differ significantly [ $t(33)=0.89$ ,  $P=0.38$ ]. Individual IQs were measured with the Wechsler abbreviated scale of intelligence (PsychCorp, Harcourt Assessment Inc., San Antonio, TX, USA). Two developmental prosopagnosics were not tested for IQ because they were unavailable for the last behavioural testing session (one has an MD and the other is working towards a PhD). The mean IQ for the other 15 developmental prosopagnosics was 123.93 ( $SD=7.83$ ) and for the controls it was 118.94 ( $SD=8.75$ ), which did not differ significantly [ $t(31)=1.71$ ,  $P=0.10$ ]. All 35 participants showed normal or corrected to normal visual acuity when tested with Test Chart 2000 (Thompson Software Solutions, Hatfield, UK).

To assess low-level perceptual abilities, developmental prosopagnosics were tested on four tasks of the Birmingham object recognition battery (Riddoch and Humphreys, 1993). The tests were 'Length match', 'Size match', 'Orientation match' and 'Position of gap'. Of the 17 developmental prosopagnosics, 16 performed these tasks. One developmental prosopagnosic did not perform the tasks because he was unavailable for testing. Individual results are presented in Supplementary Information 1, and developmental prosopagnosics' results were compared with published norms from Riddoch and Humphreys (1993). The only result significantly below the mean was from one developmental prosopagnosic on the 'Length match' test. It is unlikely, though, that this single result reveals a perceptual dysfunction in this patient. All other results from all developmental prosopagnosics were well within the normal control range according to published norms for these tests.

The developmental prosopagnosics contacted our laboratory through our website (<http://www.faceblind.org>) and reported significant difficulties recognizing familiar faces in everyday life. To ascertain that the developmental prosopagnosics did indeed have face recognition deficits, each individual was tested on the Cambridge face memory test (CFMT; Duchaine and Nakayama, 2006b) and on a Famous faces test (Duchaine and Nakayama, 2005). (See Table 1 for individual results and Supplementary Information 2 for brief descriptions of these published tasks.)

Results for each participant on the CFMT and Famous faces test were compared with previously published controls means using the modified  $t$ -test devised by Crawford and Howell (1998) for use with single cases [see Table 1; control results for the CFMT are from 50 participants from Duchaine and Nakayama (2006b), while control results for the Famous faces test are from 22 British participants described in Garrido *et al.* (2008)]. All developmental prosopagnosics had scores significantly lower than previously published controls means on both tasks, thus confirming the face recognition impairments for each patient. Table 1 also shows results from each control participant in the present study. No controls reported difficulties recognizing faces in everyday life, and all their individual scores on the CFMT were well within the normal range as previously established (Duchaine and Nakayama, 2006b). The scores of two controls on the Famous faces test were significantly below the mean, but these scores were still higher than the results from 16 developmental

**Table 1** Developmental prosopagnosics' (DP) and controls' (C) scores on two face recognition tests

Previously published control results	Cambridge face memory test $M=57.92$ ; $SD=7.91$	Famous faces test $M=0.89$ ; $SD=0.09$
DP1	36*	0.33*
DP2	43*	0.49*
DP3	35*	0.38*
DP4	37*	0.46*
DP5	32*	0.25*
DP6	40*	0.35*
DP7	37*	0.44*
DP8	32*	0.58*
DP9	37*	0.58*
DP10	26*	0.04*
DP11	34*	0.02*
DP12	36*	0.34*
DP13	28*	0.47*
DP14	41*	0.50*
DP15	41*	0.62*
DP16	38*	0.42*
DP17	29*	0.40*
C1	68	0.86
C2	66	0.95
C3	69	0.85
C4	66	0.76
C5	69	0.98
C6	69	0.98
C7	58	0.93
C8	72	0.90
C9	63	0.89
C10	60	0.77
C11	61	0.95
C12	60	0.88
C13	63	0.80
C14	59	0.69*
C15	70	0.91
C16	55	0.59*
C17	69	0.91
C18	60	0.97

Each individual score was compared with previous published results from control participants without face recognition impairments, using Crawford and Howell (1998) modified  $t$ -test. Results with an asterisk are significantly lower than the previous controls' mean with  $P<0.05$ .

prosopagnosics on this test and these two controls showed normal performance on all other face recognition tests. The control group had a mean of 64.28 ( $SD=4.99$ ) on the CFMT and 0.87 ( $SD=0.11$ ) on the Famous faces test. For the developmental prosopagnosics, the mean score on the CFMT was 35.41 ( $SD=4.78$ ) and the mean score on the Famous faces test was 0.39 ( $SD=0.17$ ). Performance was significantly different between the two groups for both the CFMT [ $t(33)=17.45$ ,  $P<0.001$ ] and the Famous faces test [ $t(33)=10.02$ ,  $P<0.001$ ].

## Behavioural tests

Participants were tested on a battery of behavioural tests tapping face and object processing so that associations between performance scores

and grey matter volume could be investigated. Results from eleven tasks were included in the present study. These tasks are all described in Supplementary Information 2.

## MRI scans

Each participant was scanned on a 3T whole body MRI scanner (Magnetom TIM Trio, Siemens Medical Systems, Erlangen, Germany) operated with a radio frequency body transmit and 12 channel receive head coil. For each participant, a T1-weighted (T1w) 3D modified driven equilibrium Fourier transform (MDEFT; Deichmann *et al.*, 2004) dataset was acquired in sagittal orientation with 1 mm isotropic resolution (176 partitions, field of view =  $256 \times 240 \text{ mm}^2$ , matrix  $256 \times 240 \times 176$ ) with the following parameters: repetition time = 7.92 ms, echo time = 2.48 ms, inversion time = 910 ms (symmetrically distributed around the inversion pulse;  $\text{quot} = 50\%$ ), flip angle  $\alpha = 16^\circ$ , fat saturation, bandwidth 195 Hz/pixel. The sequence was specifically optimized for reduced sensitivity to motion, susceptibility artefacts and B1 field inhomogeneities (Deichmann *et al.*, 2004, Howarth *et al.*, 2005).

Participants were also scanned with a multi-parameter scan protocol to estimate magnetization transfer (MT) parameter maps as an additional marker of grey and white matter (Helms *et al.*, in press). Three co-localized 3D multi-echo fast low angle shot (FLASH) datasets were acquired with predominant proton density weighting (PDw: repetition time/ $\alpha = 23.7 \text{ ms}/6^\circ$ ), T1w (18.7 ms/ $20^\circ$ ), and MTw (23.7 ms/ $6^\circ$ ; with off-resonance Gaussian saturation pulse). The images were acquired with the same resolution, matrix size and field of view as the 3D MDEFT images. The other imaging parameters were generalized autocalibrating partially parallel acquisition parallel imaging with an acceleration factor of two in the phase-encoding direction, 6/8 partial Fourier in the partition direction, bandwidth 425 Hz/pixel, total acquisition time of approximately 19 min. The signals of the first six equidistant bipolar gradient echoes (at 2.2 ms to 14.7 ms echo time) were averaged to increase the signal-to-noise ratio (Helms and Dechent, 2009). Semi-quantitative MT parameter maps, corresponding to the additional saturation created by a single MT pulse, were calculated by means of the signal amplitudes and T1 maps (Helms *et al.*, 2008a), thereby eliminating the influence of relaxation and B1 inhomogeneity (Helms *et al.*, 2008b). Multi-parameter data were not collected for three participants (2 controls and 1 developmental prosopagnosic) because of technical problems or because the participant felt uncomfortable in the scanner.

All participants were also scanned with a T2w 2D turbo spin echo sequence with the following parameters: 35 axial slices; slice thickness/gap = 3/0.9 mm; field of view =  $220 \times 220 \text{ mm}^2$ ; matrix  $512 \times 358$ ; echo time = 90 ms; repetition time = 5000 ms; effective spatial resolution of  $0.43 \times 0.61 \times 3.9 \text{ mm}^3$ . These images were not used in the statistical analysis, but utilized to rule out any gross abnormalities. A neuroradiologist (J.S.) inspected both the T1w MDEFT and T2w turbo spin echo images for all participants and did not find any such gross abnormalities.

## Data analysis

### Behavioural tests

To reduce the dimensionality of the behavioural data for further analyses, we carried out a principal component analysis using the Statistical Package for the Social Sciences 11.0 (SPSS Inc, Chicago, IL, USA). The results from the 35 participants on each task were included and components with eigenvalues higher than one were extracted.

Components were Varimax rotated and individual component scores were derived for each of the rotated components.

### Voxel-based morphometry

VBM (Ashburner and Friston, 2000; Good *et al.* 2001) is an automated procedure that permits voxel-wise analysis of grey matter volume. It was performed in Statistical Parametrical Mapping software (SPM)-5 (Wellcome Trust Centre for Neuroimaging, London, UK—<http://www.fil.ion.ucl.ac.uk/spm>) running on MATLAB 7.3.0 (Mathworks, Natick, MA, USA). The initial analysis was based on the grey matter segmented from the T1w MDEFT images. An integrated approach (unified segmentation, Ashburner and Friston, 2005) was used for bias correction, image registration to the Montreal Neurological Institute (MNI) template and tissue classification into grey matter, white matter and cerebrospinal fluid. A diffeomorphic non-linear registration tool (diffeomorphic anatomical registration through exponential lie algebra -DARTEL) was used to improve inter-subject registration (Ashburner, 2007) followed by scaling with the Jacobian determinants derived in the registration step (i.e. 'modulation'). This 'modulation' step allows for the volume of tissue from each structure to be preserved after warping. The resulting 'modulated' images were affine-transformed to MNI space and smoothed with a 12 mm full width at half maximum isotropic Gaussian kernel.

We implemented two separate general linear models: one to compare group differences in grey matter volume between developmental prosopagnosics and control participants, and one to examine any regional correlates of behavioural component scores. For both analyses, the total volume of grey matter was modelled as a linear confound. Results were considered significant only if the voxel-level family-wise error rate was lower than 0.05, corrected for multiple comparisons across the whole brain using Random Field Theory. Coordinates are given in MNI space. In addition to the whole brain analysis, anatomical masks were created for small volume correction (again with a significance level of 0.05 corrected for multiple comparisons). Areas were selected for which *a priori* hypotheses existed in relation to developmental prosopagnosia and thus involved regions of the 'core system' of face processing (Haxby *et al.* 2000) plus the anterior inferior temporal lobe (Allison *et al.*, 1994b; Behrmann *et al.*, 2007; Kriegeskorte *et al.*, 2007). All masks were taken from the Harvard-Oxford probabilistic atlas available with FSL 4.1 (FMRIB, Oxford, UK—<http://www.fmrib.ox.ac.uk/fsl>) and were thresholded at 25%. Masks were made for the inferior lateral occipital cortex, middle and posterior fusiform gyrus, mid and posterior STS (to encompass the STS we combined masks for the middle temporal gyrus (MTG) and the superior temporal gyrus), plus anterior inferior temporal lobe (including anterior fusiform, anterior inferior temporal gyrus (ITG) and ventral temporal pole). Separate masks were used for the right and left hemispheres. Supplementary Information 3 shows the extent and location of the masks.

The analyses were repeated for the MT parameter maps, since MT is considered to be a direct measure of macromolecules and myelin content unlike T1 relaxation (Tofts *et al.*, 2003; Filippi and Rocca, 2007). MT imaging has not only proved useful in clinical contexts (e.g. multiple sclerosis; Filippi and Rocca, 2007), but has also shown improved segmentation results of subcortical grey matter structures in healthy volunteers (Helms *et al.*, in press). Thus, we expected a potentially higher specificity and sensitivity to structural changes in developmental prosopagnosia from this novel VBM approach based on MT parameter maps. The analysis steps with the MT maps were the same as for the MDEFT sequence.

## Results

### Analysis based on the segmentation of T1w MDEFT images

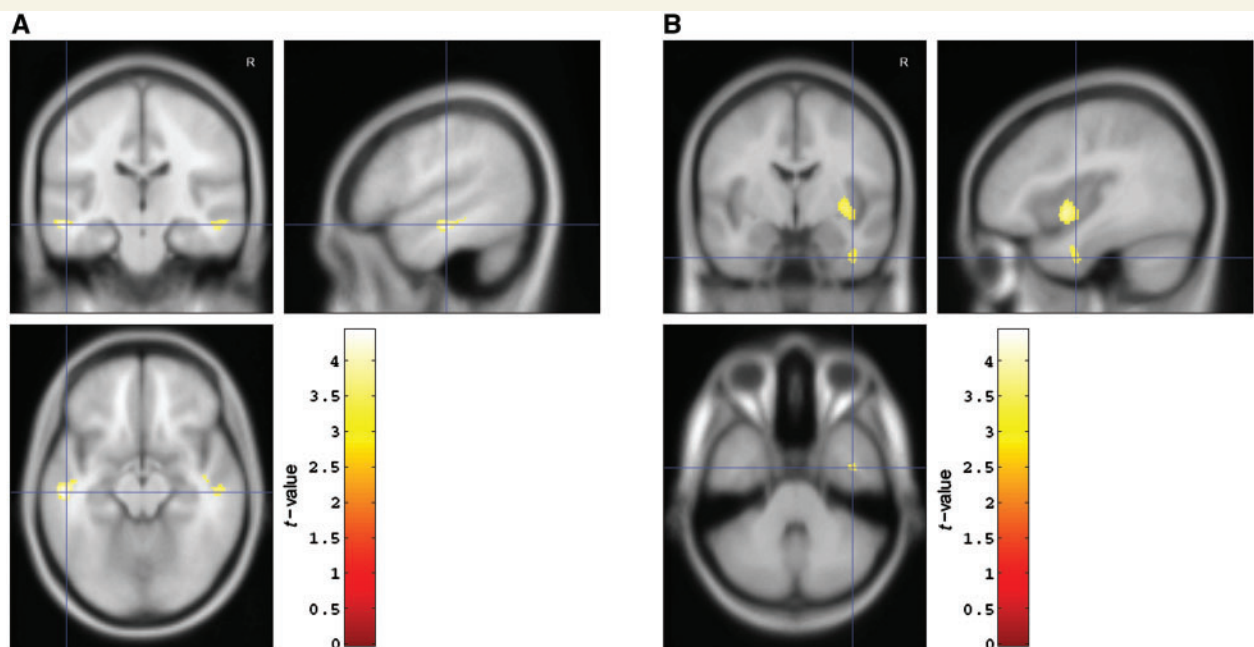
We used VBM to compare grey matter volume between the 17 developmental prosopagnosics versus 18 matched controls. For completeness only, Supplementary Information 4 shows the group differences, thresholded at 0.001 (uncorrected), when controlling for the total volume of grey matter. Correcting for multiple comparisons across the whole brain, we found no significant differences between the groups. Below we report differences family-wise error rate corrected ( $P < 0.05$ ) using small volume corrections (SVC) for *a priori* anatomical regions that included the 'core system' of face processing (Haxby *et al.*, 2000) and the anterior inferior temporal lobe (Allison *et al.*, 1994b; Behrmann *et al.*, 2007; Kriegeskorte *et al.*, 2007). Controls showed increased grey matter volume when compared with developmental prosopagnosics in the left STS/MTG [peak ( $x, y, z$ ) at  $-53, -21, -14$ ,  $t(32) = 4.41$ ,  $P = 0.011$ , SVC], right STS/MTG [peak at  $52, -18, -16$ ,  $t(32) = 3.73$ ,  $P = 0.046$ , SVC] and right anterior inferior temporal lobe [peak at  $39, -4, -35$ ,  $t(32) = 3.44$ ,  $P = 0.045$ , SVC]; see Fig. 1. No regions showed significantly greater grey matter volume for developmental prosopagnosics than controls.

We tested all participants on a battery of behavioural tests to examine their face and object recognition (for a description of the 11 tasks, see Supplementary Information 2). Our aim was to identify any regional structural correlates of these abilities.

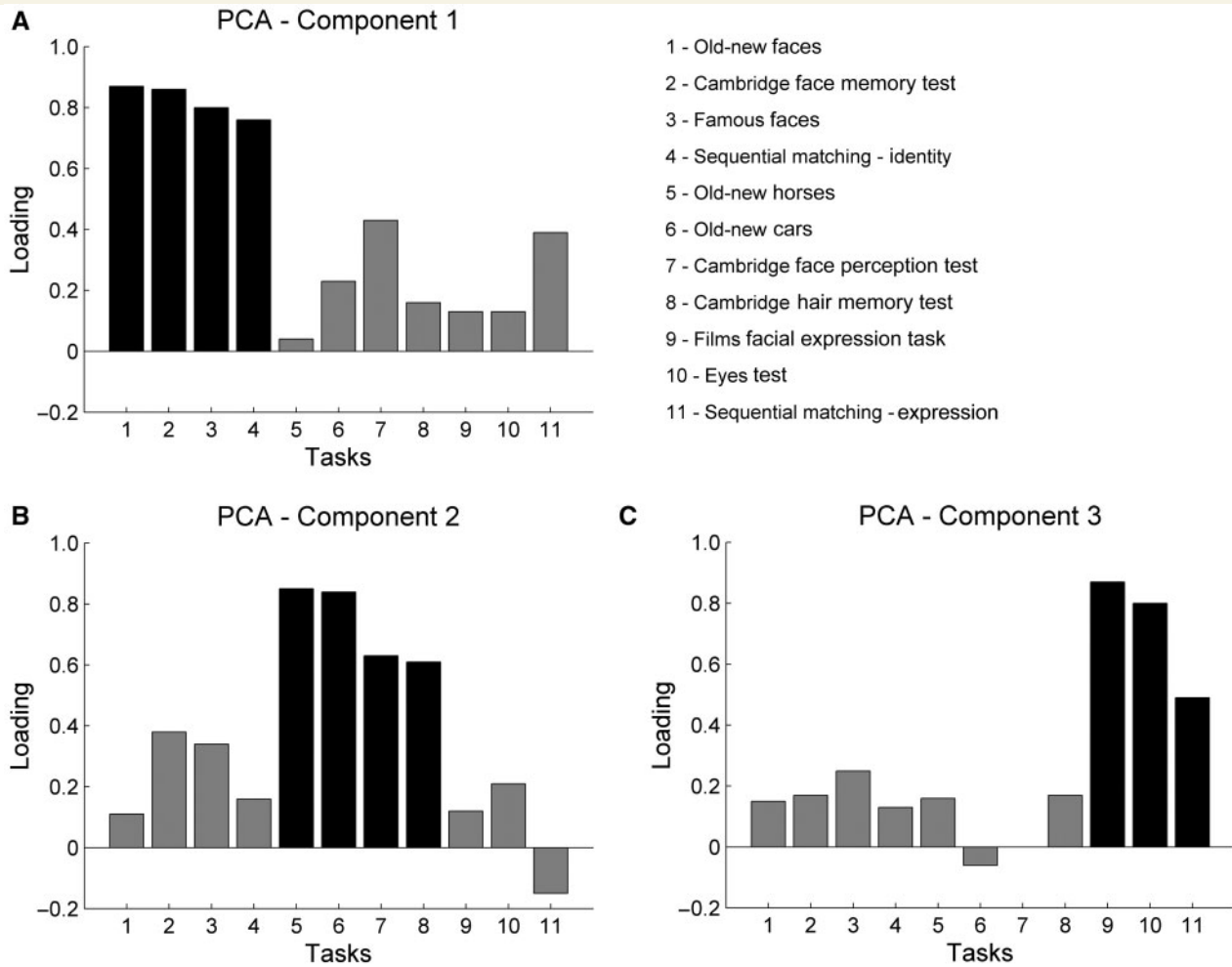
We performed a principal component analysis on the behavioural data to reduce the number of variables and observed three orthogonal components that accounted for 68.81% of the variance; see Fig. 2. The tasks with the highest loadings on the first component were all associated with facial identity, as they required encoding and recognizing faces, plus perceptual matching of facial identities. On the second component, the highest loadings were from non-face object recognition tasks, requiring the encoding and recognition of cars, horses and hairstyles. The Cambridge face perception test, a task that requires sorting faces according to their similarity, had its highest loading on this second component, even though it also loaded to some extent (0.43) on the first component. Finally, the highest loadings on the third component were all from tasks that involved the recognition of facial expressions, i.e. tasks that required matching an adjective to emotional expressions, or matching two stimuli with the same or different facial expressions.

Figure 3 shows individual component scores for each of the three principal component analysis components. Figure 3 demonstrates that the first behavioural component, related to facial identity, showed the clearest separation between the developmental prosopagnosic and control groups. In contrast, many developmental prosopagnosics had component scores similar to controls on the behavioural components related to object recognition and to facial expression.

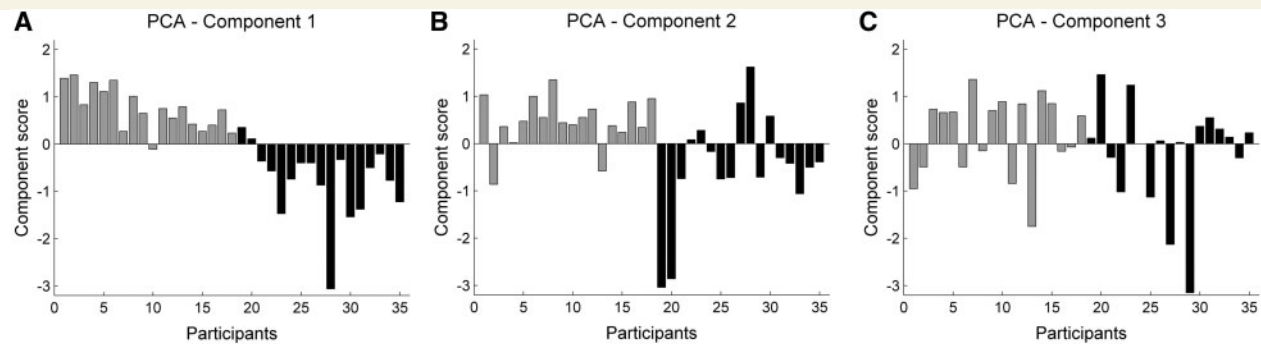
We next used individual behavioural scores for each of the three principal component analysis components in multiple regression against VBM data, while controlling for total grey matter volume. Higher scores on the first behavioural component (the one related to facial identity tasks) were associated with greater



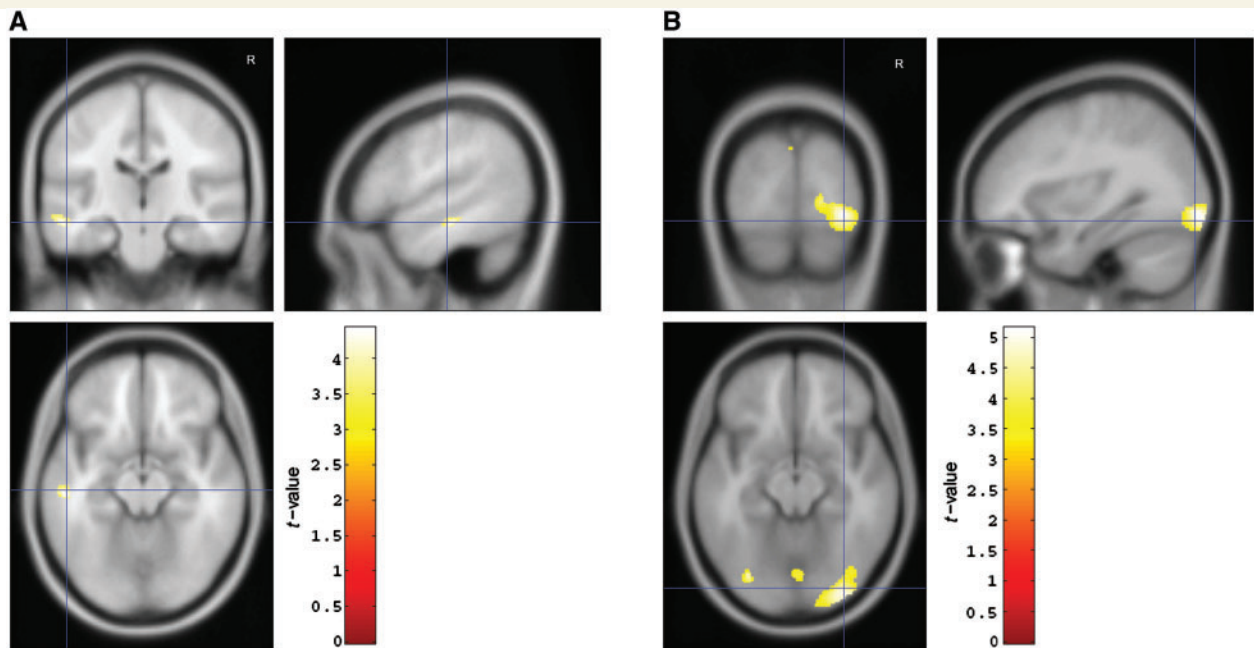
**Figure 1** Statistical parametrical maps (thresholded at  $P < 0.001$ , uncorrected for display purposes) showing regions of increased grey matter volume in controls when compared with developmental prosopagnosics via VBM. This analysis used MDEFT T1w images. Regions in (A) the left and right STS/MTG plus (B) the anterior inferior temporal lobe showed significant differences after correction for multiple comparisons using small volume corrections ( $P < 0.05$ , see main text).



**Figure 2** Loadings of each behavioural task on the three extracted principal component analysis (PCA) components, after Varimax rotation. The name of each numbered task along the x-axis is indicated in the key at top right. For description of those tasks, see Supplementary Information 2. Black bars represent the tasks for which the highest loadings were for the respective component; all black bars show loadings equal or above 0.5. The first component (A) is associated with facial identity tasks; the second component (B) is associated with non-face object recognition tasks; the third component (C) is more associated with facial expression tasks.



**Figure 3** Individual component scores for each principal component analysis (PCA) component. Each bar corresponds to one participant. The first 18 bars are from control participants, and the following 17 bars (in black) are from developmental prosopagnosics.



**Figure 4** Statistical parametric maps (thresholded at  $P < 0.001$ , uncorrected for display purposes) showing the results from the regression analysis of behavioural component scores from the principal component analysis on grey matter volume using VBM. This analysis used MDEFT T1w images. (A) Regions of increased grey matter volume in left STS/MTG associated with higher scores on the first behavioural component which relates to facial identity. (B) Regions of increased grey matter volume in the inferior lateral occipital cortex bilaterally associated with lower scores on the second behavioural component which was related to non-face object recognition. Results in (A) and (B) were both significant after correction for multiple comparisons using small volume corrections ( $P < 0.05$ ).

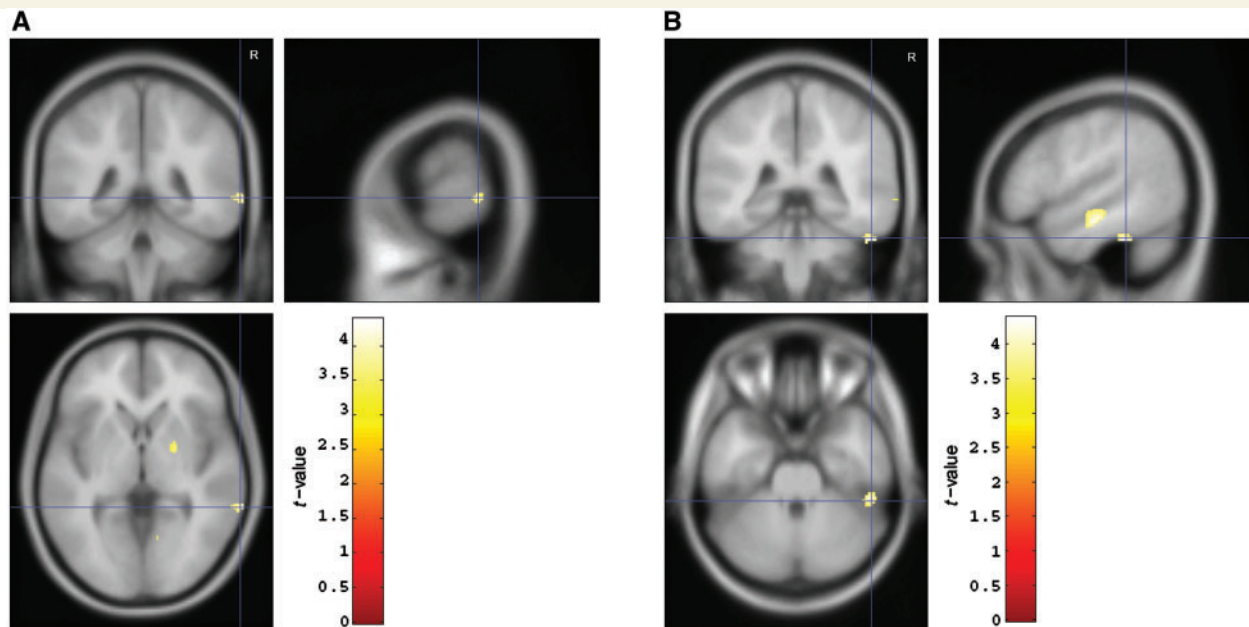
grey matter volume in the left STS/MTG [peak at  $-53, -23, -14$ ,  $t(30) = 4.37$ ,  $P = 0.013$ , SVC] (see Fig. 4). In addition, higher scores on the second component (the one related to non-face object recognition tasks) were associated with decreased grey matter volume in the inferior lateral occipital cortex bilaterally [peaks at  $32, -88, -8$ ,  $t(30) = 5.13$ ,  $P = 0.002$ ;  $38, -76, -13$ ,  $t(30) = 3.74$ ,  $P = 0.036$ ;  $-34, -81, -15$ ,  $t(30) = 3.98$ ,  $P = 0.022$ , all SVC] (see Fig. 4).

## Analysis based on the segmentation of MT parameter maps

For 32 of the participants (16 controls and 16 developmental prosopagnosics), we repeated all the analyses but now using the MT maps. For illustration only, Supplementary Information 5 shows the group differences, thresholded at 0.001 (uncorrected), when controlling for the total volume of grey matter. As with the analysis using the T1w MDEFT sequences with 35 participants, controls showed increased grey matter volume than developmental prosopagnosics in the right STS/MTG [peak at  $52, -18, -16$ ,  $t(29) = 4.18$ ,  $P = 0.021$ , SVC]. Group differences in the right anterior inferior temporal lobe and the left STS/MTG marginally failed significance [right anterior inferior temporal lobe: peak at  $41, -4, -42$ ,  $t(29) = 3.26$ ,  $P = 0.073$ , SVC; left STS/MTG: peak at  $-54, -30, -11$ ,  $t(29) = 3.51$ ,  $P = 0.087$ , SVC]. Furthermore, we found increased grey matter volume in controls when compared with developmental prosopagnosics in the right posterior STS [peak at

$69, -42, 0$ ,  $t(29) = 3.99$ ,  $P = 0.031$ , SVC], and in a more posterior region of the right fusiform gyrus/ITG [peak at  $52, -37, -30$ ,  $t(29) = 4.38$ ,  $P = 0.029$ , SVC]; see Fig. 5. In the multiple regression analysis with behavioural component scores, higher component scores related to facial identity tasks were associated with increased grey matter volume in the right middle fusiform gyrus/ITG [peak at  $48, -38, -32$ ,  $t(27) = 4.24$ ,  $P = 0.044$ , SVC]. In addition, as with the T1w MDEFT analysis, higher component scores related to non-face object recognition tasks were associated with decreased grey matter volume in the right lateral occipital cortex [peaks at  $33, -88, -9$ ,  $t(27) = 4.77$ ,  $P = 0.005$ ; and  $40, -73, -16$ ,  $t(27) = 4.42$ ,  $P = 0.010$ , both SVC].

The differences between groups in posterior STS and middle fusiform gyrus/ITG observed with the MT maps could be due to a higher sensitivity of the MT mapping approach, but could also be due to the use of a subgroup of 32 participants. To investigate whether the particular selection of participants had an impact on the observed results with the MT maps, we repeated the analysis with the segmented grey matter from the T1w MDEFT images, but now for just the same 32 participants included in the MT analysis. The T1w MDEFT-based analysis now showed a significant group difference in the posterior STS area but still not in the middle fusiform gyrus/ITG. These results suggest that the observed differences in posterior STS may relate to the specific participants included in the analysis, but it appears that the improved contrast of the MT images may be crucial for identifying the differences seen in the middle fusiform gyrus/ITG. To assess the effect of MT versus T1w imaging, we repeated the analysis



**Figure 5** Statistical parametrical maps (thresholded at  $P < 0.001$ , uncorrected for display purposes) showing regions of increased grey matter volume in controls when compared with developmental prosopagnosics. This analysis used MT parameter maps. In addition to a region in the right STS/MTG, this analysis showed that regions in (A) the right posterior STS and (B) the right middle fusiform gyrus/ITG also had significantly greater grey matter volume in controls than in developmental prosopagnosics ( $P < 0.05$ , after correction for multiple comparisons using small volume corrections).

but now with the T1w FLASH images used in the multi-parameter mapping protocol, i.e. with images that showed the same fundamental contrast as the T1w MDEFT images. The results were again consistent with the MDEFT-based results, with no significant differences seen in middle fusiform gyrus/ITG, further suggesting the higher sensitivity of MT maps in this region.

## Discussion

Individuals with developmental prosopagnosia often fail to recognize the faces of their co-workers, friends, and sometimes even their close relatives. Despite these striking face recognition deficits, developmental prosopagnosia is not accompanied by brain injury or overt gross brain abnormalities. The present study used VBM to examine whether subtle neuroanatomical abnormalities are associated with their face recognition deficits. Unlike previous structural brain studies of developmental prosopagnosia (Bentin *et al.*, 1999; Behrmann *et al.*, 2007), here we tested a relatively large sample and used an automated and unbiased method that examines the whole brain. We found that the developmental prosopagnosic group, when compared with the matched control group, showed significantly less grey matter volume in regions known to be involved in face processing. In addition, performance scores for the behavioural principal component analysis component related to facial identity tasks were associated with increased grey matter in some of these regions.

## Group differences between controls and developmental prosopagnosics

Analysis of grey matter segmented from the T1w images showed that 17 developmental prosopagnosics, when compared with 18 matched controls, had significantly decreased grey matter volume in the STS/MTG bilaterally and in the right anterior inferior temporal lobe. Furthermore, when using separately acquired MT parameter maps for tissue segmentation, we again found that developmental prosopagnosics had reduced grey matter volume in the right STS/MTG, and also in the right middle fusiform gyrus/ITG and right posterior STS. We note that, although the developmental prosopagnosics and controls were matched for gender, there were more female than male participants in both groups and therefore some caution is needed in the interpretation and generalization of these results.

The location of the observed structural differences fits nicely with studies examining the neural basis of face processing in participants with normal abilities. Numerous studies using functional neuroimaging or intracranial event related potentials have shown that the posterior and middle fusiform gyrus show selective responses to faces when compared with other objects (e.g. Allison *et al.*, 1994a; Kanwisher *et al.*, 1997). There is also evidence for involvement of the fusiform gyrus in processing facial identity from functional neuroimaging studies that show release from repetition suppression when facial identity is changed (Winston *et al.*, 2004; Rotshtein *et al.*, 2005). However, existing fMRI studies have not found consistent abnormalities in the



fusiform gyrus when responding to faces in the relatively few developmental prosopagnosics studied to date (e.g. Hasson *et al.*, 2003; Avidan *et al.*, 2005; but see Bentin *et al.*, 2007; Williams *et al.*, 2007). Moreover, Behrmann *et al.* (2007) only reported structural abnormalities in the anterior fusiform gyrus of six developmental prosopagnosics. Here for the first time we were able to show that developmental prosopagnosics have reduced grey matter volume in a more posterior region of the fusiform gyrus/ITG. This result identifies a new subtle neural correlate of developmental prosopagnosia, and in doing so it also adds new convergent evidence for existing proposals that this region contributes to face recognition.

The observed group difference in the middle fusiform gyrus/ITG was only evident when using the MT maps, but not when using the T1w images which are currently the standard contrast for morphometric studies. There are several possible explanations for this difference between the two types of images. The MT contrast is considered to provide a more direct measure of macromolecular content and myelination (Fillipi and Rocca, 2007). It may therefore be more sensitive to any changes in myelination or macromolecular content possibly arising in developmental prosopagnosia, thus affecting automated tissue classification (segmentation) due to differences in signal intensity. A generally improved segmentation of brain tissue with MT maps may also have led to a higher sensitivity for small morphological changes. Segmentation is facilitated by the insensitivity of MT maps to radio frequency transmit bias at 3T, which causes signal and contrast changes across the brain (Helms *et al.*, 2008b), and to T1 changes due to iron deposition (Helms *et al.*, in press). The improved contrast-to-noise ratio in MT maps has been shown to yield more reliable segmentation of subcortical grey matter structures in healthy volunteers (Helms *et al.*, in press). Although we cannot unambiguously attribute the observed differences between MT and T1w to a particular cause, the use of MT maps appears promising and the profile found here may offer some clues regarding the potential nature of the structural changes associated with developmental prosopagnosia (e.g. potentially involving macromolecular content and/or myelination).

We also found that developmental prosopagnosics tended to have reduced grey matter volume in a more anterior region of the right anterior inferior temporal lobe (for the MT maps it approached significance). This is consistent with results from Behrmann *et al.* (2007), who also found smaller anterior fusiform gyri in six developmental prosopagnosics using volumetric analysis. Like more posterior regions of the fusiform gyrus, a region in the right anterior inferior temporal lobe also shows significantly higher responses to faces than scrambled faces and objects (Allison *et al.*, 1994b, 1999; Tsao *et al.*, 2008; Rajimehr *et al.*, 2009). PET studies have further suggested the involvement of medial anterior temporal regions and temporal poles in processing famous or familiar faces (Sergent *et al.*, 1992; Nakamura *et al.*, 2000), and a recent fMRI study found that the activity pattern in the right anterior inferior temporal lobe, but not in the fusiform face area could differentiate between two faces (Kriegeskorte *et al.*, 2007). These results strongly suggest the involvement of the anterior inferior temporal cortex in normal processing of facial identity. There are also several studies of patients with acquired

prosopagnosia whose lesions predominantly affected the anterior temporal lobe (e.g. Damasio *et al.*, 1990; Tranel *et al.*, 1997; Barton, 2008). However, some patient studies have suggested that atrophy in the right anterior temporal lobe leads not only to prosopagnosia, but also to impaired recognition of people from other modalities, for example via names and voices (Evans *et al.*, 1995; Gainotti *et al.*, 2003). The latter impairments appear to be uncommon in developmental prosopagnosia, as the affected participants tested in our laboratory typically report that they can recognize people by their voices, names, and gait (see von Kriegstein *et al.*, 2008 for a group of developmental prosopagnosics with normal voice recognition). Nevertheless, these remain to be formally tested in the present group of developmental prosopagnosics.

Finally, we found that developmental prosopagnosics had decreased grey matter volume in the mid STS/MTG bilaterally (for the MT maps, significant differences were only observed in the right hemisphere) and right posterior STS. These results contrast with the volumetric analysis by Behrmann *et al.* (2007) that reported that their developmental prosopagnosics had larger anterior and posterior MTG than controls. Like the other areas exhibiting group differences in the present study, regions in the posterior STS show stronger responses to faces versus other objects on functional neuroimaging or intracranial event related potential studies (e.g. Allison *et al.*, 1999; Winston *et al.*, 2004). In all our analyses using a subsample of 32 from the 35 participants, we found significant differences between groups in this posterior STS region. However, our analysis that involved all 35 participants failed to show this result significantly. The apparent differences in the posterior STS thus merit further investigation and may be more variable between developmental prosopagnosic individuals.

The regions in the STS for which we found more robust group structural differences were more anterior. Some functional neuroimaging studies have also found face-selective responses in the mid STS (Scherf *et al.*, 2007; Fox *et al.*, 2009a), with more participants showing face-selective responses in the mid STS when dynamic faces and objects are presented instead of static images (Fox *et al.*, 2009a). Little is known currently, however, about the functional role of mid STS/MTG in face processing. Two studies investigating repetition suppression for facial identities and facial expressions found decreased fMRI responses in the mid STS when the same expression was repeated (Winston *et al.*, 2004; Fox *et al.*, 2009b). Given that most developmental prosopagnosics we tested do not show difficulties processing facial expressions (see Fig. 3), it seems unlikely that the decreased grey matter volume in the STS of developmental prosopagnosics is associated with processing of facial expressions, and we found no such brain-behaviour association here. Instead, we found that grey matter volume in left STS was associated with the behavioural component scores related to facial identity tasks. Functional neuroimaging studies have also shown the involvement of anterior/mid regions of the STS and MTG in processing facial identity information, especially in tasks comparing viewing of famous faces to non-familiar faces (Sergent *et al.*, 1992; Gorno Tempini *et al.*, 1998; Leveroni *et al.*, 2000; Sugiura *et al.*, 2001). Rotshtein *et al.* (2005) also found that this region (among others) was sensitive to change in identities

between two famous faces. Some of the regions identified in those studies appear to be slightly more anterior than the regions where we found structural group differences in the current study, but others overlap with the regions in which we found differences between developmental prosopagnosics and controls (Gorno Tempini *et al.*, 1998; Leveroni *et al.*, 2000).

Our results show that developmental prosopagnosics have reduced grey matter volume in several regions of the face processing system. The developmental events that lead to these differences will be an interesting avenue for future exploration. Differences in distinct areas may have resulted from separate neurodevelopmental anomalies, or abnormalities in certain regions may then have led to reduced grey matter in other areas. It will be interesting to investigate how these structural differences relate to functional responses in developmental prosopagnosics and how they relate to specific computations necessary for face recognition. Even though face-selective responses have been shown in all the regions for which we found reduced grey matter in developmental prosopagnosics here, as yet there is still only an elementary understanding about the probable functions of these regions. In an attempt to shed further light on this issue, here we also investigated associations between structural brain measures and performance on behavioural tests.

## Associations of brain structure with behaviour

All participants were tested on a large battery of behavioural tests measuring face and object processing. A principal component analysis of these results for all participants yielded three components, one associated with facial identity tasks, one with non-face object recognition tasks and one with facial expressions tasks. These results are consistent with previous claims that face and object processing mechanisms are dissociable (e.g. Farah *et al.*, 1995; Moscovitch *et al.*, 1997; Duchaine *et al.*, 2006), and that facial identity and facial expressions can be processed separately (e.g. Bruce and Young, 1986; Haxby *et al.*, 2000). Moreover, this principal component analysis allowed us to obtain a composite behavioural score of facial identity abilities, via the first principal component.

We found that higher behavioural component scores related to facial identity were associated with increased grey matter volume in the left STS/MTG. In addition, with the MT maps we found that higher component scores related to facial identity were associated with increased grey matter volume in the right middle fusiform gyrus/ITG. These results were expected given the group differences between developmental prosopagnosics and controls, but they further suggest that the differences between groups in these regions are associated with differences in performance that are specific to facial identity. We did not find such significant correlations with the behavioural facial identity component for the other regions in which we had found group structural differences, namely the right STS/MTG and the right anterior inferior temporal lobe. It could be that these regions are also important for performance in object recognition and facial expression tasks. It is also possible that the relationship between identity

scores and grey matter volume in these regions followed different patterns within each group, and therefore the variability across all participants did not follow a linear pattern. In the present study, we focused on the variability across all participants related to the behavioural components, but other studies, using even larger groups of participants, could additionally investigate the variability within each group.

We found that higher behavioural component scores related to object recognition tests were associated with decreased grey matter volume in the inferior lateral occipital cortex. Functional neuroimaging has shown that separate regions of the lateral occipital cortex are associated with processing objects (Malach *et al.*, 1995) and faces (Gauthier *et al.*, 2000). Given that these regions are defined functionally, inferring an association between the structural results and one of these regions is problematic. In any case, our results show a new association between neuroanatomical structure in the lateral occipital cortex and object recognition abilities.

An apparent paradox may seem to arise from better performance on face recognition tasks being associated with increased grey matter volume in the left STS/MTG and right middle fusiform gyrus/ITG, while better performance in object recognition tasks was associated with decreased grey matter volume in lateral occipital cortex. However, increased grey matter volume measured with VBM can result from several factors, including differences at the cellular level, different folding patterns or thicker cortex (Ashburner and Friston, 2001; Mechelli *et al.*, 2005). A full understanding of how behavioural performance relates to grey matter volume will ultimately require detailed study defining which of these possibilities underlies the observed differences.

Throughout the article, we have referred to the results in VBM as being related to grey matter volume. We note, however, that when significant group differences are observed in VBM there are alternative explanations for those differences (Ashburner and Friston, 2001). The most common criticism of VBM is that it is sensitive to differences caused by mis-registration during spatial normalization (Bookstein, 2001). VBM will only detect systematic group differences, but systematic differences in registration are indeed a possible cause of observed group differences, as are systematic differences in tissue classification (Ashburner and Friston, 2001). However, recent developments in segmentation and registration methods have improved the specificity so that observed group differences are more likely to be caused by differences in grey matter volume in the identified locations. The use of unified segmentation (Ashburner and Friston, 2005) and especially the use of DARTEL (Ashburner, 2007), as we did in the present study, is expected to result in better tissue classification and improved registration between subjects. DARTEL uses many more parameters to explain the shape of the brain than any algorithm previously used in SPM, thus achieving more precise registration between subjects. An evaluation of 14 non-linear registration methods showed that inter-subject registration performed with DARTEL led to much better results than previous approaches in SPM (Klein *et al.* 2009). (For a full discussion of limitations of VBM see Bookstein, 2001; Ashburner and Friston, 2001; Mechelli *et al.* 2005; Ashburner, in press).

## Summary

To conclude, we used VBM to investigate subtle neuroanatomical differences in developmental prosopagnosia, using a relatively large sample of developmental prosopagnosics compared with matched controls. We found that the developmental prosopagnosics showed decreased grey matter volume in the right middle fusiform gyrus/ITG, mid STS/MTG bilaterally and right anterior inferior temporal lobe. Our results indicate that developmental prosopagnosia is associated with structural changes in several regions that are known to show face selectivity (Allison *et al.*, 1999; Scherf *et al.*, 2007; Tsao *et al.*, 2008; Rajimehr *et al.*, 2009; Fox *et al.*, 2009a). The association between behavioural component scores and regional grey matter further suggest that grey matter volume in the left STS/MTG and the right middle fusiform gyrus/ITG is related to performance on facial identity tasks. These results provide new evidence that integrity of these brain areas is necessary for successful face recognition and illustrate that studies of developmental prosopagnosia can offer a fruitful approach to understand their role.

## Acknowledgements

The authors are very grateful to all developmental prosopagnosic and control participants for their time and enthusiastic participation. They thank John Ashburner and Karl Friston for very helpful discussions and suggestions about the methods, Laura Germaine and Raka Tavashmi for help with testing developmental prosopagnosics, the Physics group at the FIL for their support and input, and the radiographers at the FIL for help with scanning.

## Funding

Funding for this work was provided by grants from the Portuguese Foundation for Science and Technology (studentship SFRH/BD/22580/2005 to L.G.), the Economic and Social Research Council (RES-061-23-0400 to B.D.); the Wellcome Trust (Wellcome Trust Programme Grant to R.J.D.).

## References

Allison T, Ginter H, McCarthy G, Nobre AC, Puce A, Luby M, et al. Face recognition in human extrastriate cortex. *J Neurophysiol* 1994a; 71: 821–5.

Allison T, McCarthy G, Nobre AC, Puce A, Belger A. Human extrastriate visual cortex and the perception of faces, words, numbers and colors. *Cereb Cortex* 1994b; 5: 544–54.

Allison T, Puce A, Spencer D, McCarthy G. Electrophysiological studies of human face perception. I: Potentials generated in occipitotemporal cortex by face and non-face stimuli. *Cerebral Cortex* 1999; 9: 415–30.

Ashburner J. A fast diffeomorphic image registration algorithm. *Neuroimage* 2007; 38: 95–113.

Ashburner J. Computational anatomy with the SPM software. *Magn Reson Imaging* 2009; 0: 0Epub ahead of print.

Ashburner J, Friston K. Voxel-based morphometry – the methods. *Neuroimage* 2000; 11: 805–21.

Ashburner J, Friston K. Why voxel-based morphometry should be used. *Neuroimage* 2001; 14: 1238–43.

Ashburner J, Friston K. Unified segmentation. *Neuroimage* 2005; 26: 839–51.

Ashburner J, Csernansky J, Davatzikos C, Fox N, Frisoni G, Thompson P. Computer-assisted imaging to assess brain structure in healthy and diseased brains. *Lancet Neurol* 2003; 2: 79–88.

Avidan G, Hasson U, Malach R, Behrmann M. Detailed exploration of face-related processing in congenital prosopagnosia: 2. Functional neuroimaging findings. *J Cogn Neurosci* 2005; 17: 1150–67.

Barton J. Structure and function in acquired prosopagnosia: lessons from a series of 10 patients with brain damage. *Journal of Neuropsychology* 2008; 2: 197–225.

Barton J, Press D, Keenan J, O'Connor M. Lesions of the fusiform face area impair perception of facial configuration in prosopagnosia. *Neurology* 2002; 58: 71–8.

Behrmann M, Avidan G. Congenital prosopagnosia: face-blind from birth. *Trends Cogn Sci* 2005; 9: 180–7.

Behrmann M, Avidan G, Gao F, Black S. Structural imaging reveals anatomical alterations in inferotemporal cortex in congenital prosopagnosia. *Cereb Cortex* 2007; 17: 2354–63.

Bentin S, DeGutis J, D'Esposito M, Robertson LC. Too many trees to see the forest: Performance, event-related potential, and functional magnetic resonance imaging manifestations of integrative congenital prosopagnosia. *J Cogn Neurosci* 2007; 19: 132–46.

Bentin S, Deouell LY, Soroker N. Selective visual streaming in face recognition: evidence from developmental prosopagnosia. *Neuroreport* 1999; 10: 823–7.

Bodamer J. Die prosopagnosie. *Archiv für Psychiatrie und Nervenkrankheiten* 1947; 179: 6–53.

Bookstein F. "Voxel-based morphometry" should not be used with imperfectly registered images. *Neuroimage* 2001; 14: 1454–62.

Bornstein B. Prosopagnosia. In: Halpern L, editor. Problems of dynamic neurology, an international volume: studies of the higher functions of the human nervous system. Jerusalem, Israel: The Department of Nervous Diseases of the Rothschild Hadassah University Hospital and the Hebrew University Hadassah Medical School; 1963. p. 283–318.

Bouvier S, Engel S. Behavioral deficits and cortical damage loci in cerebral achromatopsia. *Cereb Cortex* 2006; 16: 183–91.

Bruce V, Young A. Understanding face recognition. *Br J Psychol* 1986; 77 (Pt 3): 305–27.

Crawford JR, Howell DC. Comparing an individual's test score against norms derived from small samples. *Clin Neuropsychol* 1998; 12: 482–6.

Damasio AR, Damasio H, Van Hoesen GW. Prosopagnosia: anatomic basis and behavioral mechanisms. *Neurology* 1982; 32: 331–41.

Damasio AR, Tranel D, Damasio H. Face agnosia and the neural substrates of memory. *Ann Rev Neurosci* 1990; 13: 89–109.

Deichmann R, Schwarzbauer C, Turner R. Optimisation of the 3D MDEFT sequence for anatomical brain imaging: technical implications at 1.5 and 3T. *Neuroimage* 2004; 21: 757–67.

De Renzi E. Prosopagnosia in two patients with CT scan evidence of damage confined to the right hemisphere. *Neuropsychologia* 1986; 24: 385–9.

Draganski B, Gaser C, Busch V, Schuierer G, Bogdahn U, May A. Changes in grey matter induced by training. *Nature* 2004; 427: 311–2.

Duchaine B, Nakayama K. Dissociations of face and object recognition in developmental prosopagnosia. *J Cogn Neurosci* 2005; 17: 249–61.

Duchaine BC, Nakayama K. Developmental prosopagnosia: a window to content-specific face processing. *Curr Opin Neurobiol* 2006a; 16: 166–73.

Duchaine B, Nakayama K. The Cambridge Face Memory Test: Results for neurologically intact individuals and an investigation of its validity using inverted face stimuli and prosopagnosic participants. *Neuropsychologia* 2006b; 44: 576–85.

Duchaine BC, Yovel G, Butterworth B, Nakayama K. Prosopagnosia as an impairment to face-specific mechanisms: Elimination of the alternative

- hypotheses in a developmental case. *Cogn Neuropsychol* 2006; 23: 714–47.
- Evans J, Heggs A, Antoun N, Hodges J. Progressive prosopagnosia associated with selective right temporal lobe atrophy: a new syndrome? *Brain* 1995; 118: 1–13.
- Farah M, Levinson K, Klein K. Face perception and within-category discrimination in prosopagnosia. *Neuropsychologia* 1995; 33: 661–74.
- Filippi M, Rocca M. Magnetization transfer magnetic resonance imaging of the brain, spinal cord and optic nerve. *Neurotherapeutics* 2007; 4: 401–13.
- Fox C, Iaria G, Barton J. Defining the face processing network: Optimization of the functional localizer in fMRI. *Hum Brain Map* 2009a; 30: 1637–51.
- Fox C, Moon S, Iaria G, Barton J. The correlates of subjective perception of identity and expression in the face network: an fMRI adaptation study. *Neuroimage* 2009b; 44: 569–80.
- Gainotti G, Barbier A, Marra C. Slowly progressive defect in recognition of familiar people in a patient with right anterior temporal atrophy. *Brain* 2003; 126: 792–803.
- Garrido L, Nakayama K, Duchaine B. Face detection in normal and prosopagnosic individuals. *J Neuropsychol* 2008; 2: 119–40.
- Gauthier I, Tarr MJ, Moylan G, Skudlarski P, Gore JC, Anderson A. The fusiform “face area” is part of a network that processes faces at the individual level. *Journal of Cognitive Neuroscience* 2000; 12: 495–504.
- Good C, Johnsrude I, Ashburner J, Henson R, Friston K, Frackowiak RS. A voxel-based morphometric study of ageing in 465 normal adult brains. *Neuroimage* 2001; 14: 21–36.
- Gorno Tempini M, Price C, Josephs O, Vandenberghe R, Cappa S, Kapur N, *et al.* The neural systems sustaining face and proper-name processing. *Brain* 1998; 121: 2103–18.
- Grill-Spector K, Knouf N, Kanwisher N. The fusiform face area subserves face perception, not generic within-category identification. *Nat Neurosci* 2004; 7: 555–62.
- Grill-Spector K, Malach R. fMR-adaptation: a tool for studying the functional properties of human cortical neurons. *Acta Psychologica (Amst)* 2001; 107: 293–321.
- Hasson U, Avidan G, Deouell LY, Bentin S, Malach R. Face-selective activation in a congenital prosopagnosic subject. *J Cogn Neurosci* 2003; 15: 419–31.
- Haxby JV, Hoffman EA, Gobbini MI. The distributed human neural system for face perception. *Trends Cogn Sci* 2000; 4: 223–33.
- Helms G, Dathe H, Dechent P. Quantitative FLASH MRI at 3T using a rational approximation of the Ernst equation. *Mag Reson Med* 2008a; 59: 667–72.
- Helms G, Dathe H, Kallenberg K, Dechent P. High-resolution maps of magnetization transfer with inherent correction for RF inhomogeneity and T1 relaxation obtained from a 3D FLASH MRI. *Mag Reson Med* 2008b; 60: 1396–407.
- Helms G, Dechent P. Increased SNR and reduced distortions by averaging multiple gradient echo signals in 3D FLASH imaging of the human brain at 3T. *J Magn Reson Imaging* 2009; 29: 198–204.
- Helms G, Draganski B, Frackowiak RS, Ashburner J, Weiskopf N. Improved segmentation of deep brain grey matter structures using magnetization transfer (MT) maps. *Neuroimage* 2009; Epub ahead of print.
- Howarth C, Hutton C, Deichmann R. Improvement of the image quality of T1-weighted anatomical brain scans. *Neuroimage* 2005; 29: 930–7.
- Humphreys K, Avidan G, Behrmann M. A detailed investigation of facial expression processing in congenital prosopagnosia as compared to acquired prosopagnosia. *Exp Brain Res* 2007; 176: 356–73.
- Hyde K, Zatorre R, Griffiths T, Perch J, Peretz I. Morphometry of the amusic brain: a two-site study. *Brain* 2006; 129: 2562–70.
- Kanwisher N, McDermott J, Chun MM. The fusiform face area: a module in human extrastriate cortex specialized for face perception. *J Neurosci* 1997; 17: 4302–11.
- Karas G, Scheltens P, Rombouts S, Visser P, van Schijndel R, Fox N, *et al.* Global and local grey matter loss in mild cognitive impairment and Alzheimer’s disease. *Neuroimage* 2004; 23: 708–16.
- Klein A, Asdersson J, Ardekani B, Ashburner J, Avants B, Chiang M, *et al.* Evaluation of 14 nonlinear deformation algorithms applied to human brain MRI registration. *Neuroimage* 2009; 46: 786–802.
- Kress T, Daum I. Developmental prosopagnosia: a review. *Behav Neurosci* 2003; 14: 109–21.
- Kriegeskorte N, Formisano E, Sorger B, Goebel R. Individual faces elicit distinct response patterns in human anterior temporal cortex. *Proc Natl Acad Sci USA* 2007; 104: 20600–5.
- Kubicki M, Shenton M, Salisbury D, Hirayasu Y, Kasai K, Kikinis R, *et al.* Voxel-based morphometric analysis of grey matter in first episode schizophrenia. *Neuroimage* 2002; 17: 1711–9.
- Leveroni C, Seidenberg M, Mayer A, Mead L, Binder J, Rao S. Neural systems underlying the recognition of familiar and newly learned faces. *Journal of Neuroscience* 2000; 20: 878–86.
- Maguire E, Gadian D, Johnsrude I, Good C, Ashburner J, Frackowiak RS, *et al.* Navigation-related structural change in the hippocampi of taxi drivers. *Proc Natl Acad Sci USA* 2000; 97: 4398–403.
- Malach R, Reppas J, Benson R, Kwong K, Jiang H, Kennedy W, *et al.* Object-related activity revealed by functional magnetic resonance imaging in human occipital cortex. *Proc Natl Acad Sci USA* 1995; 92: 8135–9.
- Mechelli A, Crinion J, Noppeney U, O’Doherty J, Ashburner J, Frackowiak RS, *et al.* Neurolinguistics: structural plasticity in the bilingual brain. *Nature* 2004; 431: 757.
- Mechelli A, Price CJ, Friston K, Ashburner J. Voxel-based morphometry of the human brain: Methods and applications. *Cur Med Imaging Reviews* 2005; 1: 1–9.
- McConachie HR. Developmental prosopagnosia. A single case report. *Cortex* 1976; 12: 76–82.
- Minnebusch D, Suchan B, Köster O, Daum I. A bilateral occipitotemporal network mediates face perception. *Behav Brain Res* 2009; 198: 179–85.
- Moscovitch M, Winocur G, Behrmann M. What is special about face recognition? Nineteen experiments on a person with visual object agnosia and dyslexia but normal face recognition. *J Cogn Neurosci* 1997; 9: 555–604.
- Nakamura K, Kawashima R, Sato N, Nakamura A, Sugiura M, Kato T, *et al.* Functional delineation of the human occipito-temporal areas related to face and scene processing. A PET study. *Brain* 2000; 123: 1903–12.
- Pitcher D, Charles L, Devlin J, Walsh V, Duchaine B. Triple dissociation of faces, bodies, and objects in extrastriate cortex. *Cur Biol* 2009; 19: 319–24.
- Rajimehr R, Young JC, Tootell R. An anterior temporal face patch in human cortex, predicted by macaque maps. *Proc Natl Acad Sci USA* 2009; 106: 1995–2000.
- Riddoch MJ, Humphreys GW. *BORB: Birmingham object recognition battery*. Hove, UK: Erlbaum; 1993.
- Rossion B, Caldara R, Seghier M, Schuller AM, Lazeyras F, Mayer E. A network of occipito-temporal face-sensitive areas besides the right middle fusiform gyrus is necessary for normal face processing. *Brain* 2003; 126 (Pt 11): 2381–95.
- Rotshtein P, Henson R, Treves A, Driver J, Dolan R. Morphing Marilyn into Maggie dissociates physical and identity face representations in the brain. *Nat Neurosci* 2005; 8: 107–13.
- Scherf KS, Behrmann M, Humphreys K, Luna B. Visual category-selectivity for faces, places and objects emerges along different developmental trajectories. *Dev Sci* 2007; 10: F15–F30.
- Sergent J, Ohta S, MacDonald B. Functional neuroanatomy of face and object processing. A positron emission tomography study. *Brain* 1992; 115: 15–36.
- Silani G, Frith U, Demonet J, Fazio F, Perani D, Price C, *et al.* Brain abnormalities underlying altered activation in dyslexia: a voxel based morphometry study. *Brain* 2005; 128: 2453–61.

- Sugiura M, Kawashima R, Nakamura K, Sato N, Nakamura A, Kato T, et al. Activation reduction in anterior temporal cortices during repeated recognition of faces of personal acquaintances. *Neuroimage* 2001; 13: 877–90.
- Tofts P, Steens S, van Buchem M. MT: Magnetization transfer. In: Tofts P, editor. *Quantitative MRI of the brain: measuring changes caused by disease*. Chichester, West Sussex, England: John Wiley & Sons; 2003. p. 257–98.
- Tranel D, Damasio H, Damasio AR. A neural basis for the retrieval of conceptual knowledge. *Neuropsychologia* 1997; 35: 1319–27.
- Tsao D, Moeller S, Freiwald W. Comparing face patch systems in macaques and humans. *Proc Natl Acad Sci USA* 2008; 105: 19513–8.
- Van den Stock J, van de Riet W, Righart R, de Gelder B. Neural correlates of perceiving emotional faces and bodies in developmental prosopagnosia: An event-related fMRI study. *PLoS ONE* 2008; 3: e3195.
- von Kriegstein K, Dogan O, Grüter M, Giraud A, Kell C, Grüter T, et al. Simulation of talking faces in the human brain improves auditory speech recognition. *Proc Natl Acad Sci USA* 2008; 105: 6747–52.
- Wada Y, Yamamoto T. Selective impairment of facial recognition due to a hematoma restricted to the right fusiform and lateral occipital region. *Journal of Neurology, Neurosurg Psychiatry* 2001; 71: 254–7.
- Williams M, Berberovic N, Mattingley J. Abnormal fMRI adaptation to unfamiliar faces in a case of developmental prosopagnosia. *Cur Biol* 2007; 17: 1259–64.
- Winston JS, Henson RN, Fine-Goulden MR, Dolan RJ. fMRI-adaptation reveals dissociable neural representations of identity and expression in face perception. *J Neurophysiol* 2004; 92: 1830–9.
- Yovel G, Kanwisher N. The neural basis of the behavioral face-inversion effect. *Cur Biol* 2005; 15: 2256–62.