

2 **Amidst an amygdala renaissance in Alzheimer's disease**

3 Kaitlin M. Stouffer,^{1,2,3} Xenia Grande,^{4,5} Emrah Duezel,^{4,5} Maurits Johansson,^{6,7,8} Byron
4 Creese,^{9,10} Menno P. Witter,^{11,12} Michael I. Miller,^{1,2,3} Laura E. M. Wisse^{13,†} and David
5 Berron^{4,6,†}

6 †These authors contributed equally to this work.

7 **Abstract**

8 The amygdala was highlighted as an early site for neurofibrillary tau tangle pathology in
9 Alzheimer's disease in the seminal Braak & Braak article (1991). This knowledge has, however,
10 only received traction recently with advances in imaging and image analysis techniques. Here, we
11 provide a cross-disciplinary overview of pathology and neuroimaging studies on the amygdala.
12 These studies provide strong support for an early role of the amygdala in Alzheimer's disease and
13 the utility of imaging biomarkers of the amygdala in detecting early changes and predicting decline
14 in cognitive functions and neuropsychiatric symptoms in early stages. We summarize the animal
15 literature on connectivity of the amygdala, demonstrating that amygdala nuclei that show the
16 earliest and strongest accumulation of neurofibrillary tangle pathology are those that are connected
17 to brain regions that also show early neurofibrillary tangle accumulation. Additionally, we propose
18 an alternative pathway of neurofibrillary tangle spreading within the medial temporal lobe between
19 the amygdala and the anterior hippocampus. The proposed existence of this pathway is
20 strengthened by novel experimental data on human functional connectivity. Finally, we summarize
21 the functional roles of the amygdala, highlighting the correspondence between neurofibrillary
22 tangle accumulation and symptomatic profiles in Alzheimer's disease. In summary, these findings
23 provide a new impetus for studying the amygdala in Alzheimer's disease and a unique perspective
24 to guide further study on neurofibrillary tangle spreading and the occurrence of neuropsychiatric
25 symptoms in Alzheimer's disease.

26

27

1 **Author affiliations:**

2 1 Department of Biomedical Engineering, Johns Hopkins University, Baltimore, MD, 21218, USA

3 2 Kavli Neuroscience Discovery Institute, Johns Hopkins University, Baltimore, MD, 21218, USA

4 3 Center for Imaging Science, Johns Hopkins University, Baltimore, MD, 21218, USA

5 4 German Center for Neurodegenerative Diseases (DZNE), 39120, Magdeburg, Germany

6 5 Institute for Cognitive Neurology and Dementia Research, Otto-von-Guericke University,
7 39106, Magdeburg, Germany

8 6 Clinical Memory Research Unit, Department of Clinical Sciences Malmö, Lund University, 205
9 02, Lund, Sweden

10 7 Division of Clinical Sciences, Helsingborg, Department of Clinical Sciences Lund, Lund
11 University, 221 84, Lund, Sweden

12 8 Department of Psychiatry, Helsingborg Hospital, 252 23, Helsingborg, Sweden

13 9 Department of Clinical and Biomedical Sciences, Faculty of Health and Life Sciences,
14 University of Exeter, EX4 4PY, Exeter, UK

15 10 Division of Psychology, Department of Life Sciences, Brunel University London, UB8 3PH,
16 Uxbridge, UK

17 11 Kavli Institute for Systems Neuroscience, NTNU Norwegian University of Science and
18 Technology, 7491, Trondheim, Norway

19 12 KG. Jebsen Centre for Alzheimer's Disease, NTNU Norwegian University of Science and
20 Technology, 7491, Trondheim, Norway

21 13 Diagnostic Radiology, Department of Clinical Sciences Lund, Lund University, 211 84, Lund,
22 Sweden

23

24 Correspondence to: Kaitlin Stouffer

25 Full postal address: 307D Clark Hall, Johns Hopkins University, 3400 N Charles St, Baltimore,
26 MD, 21218, USA

1 E-mail: kstouff4@jhmi.edu

2

3 Correspondence may also be addressed to: David Berron

4 Full postal address: German Center for Neurodegenerative Diseases (DZNE), Leipziger Straße 44,
5 39120 Magdeburg, Germany

6 E-mail: david.berron@med.lu.se

7

8 **Running title:** Amygdala in Alzheimer's disease

9

10 **Keywords:** Alzheimer's disease; amygdala; tau pathology; neuropsychiatric symptoms; clinical
11 imaging biomarkers; medial temporal lobe connectivity

12

13 **Introduction**

14 Alzheimer's disease (AD) is one of the most heavily studied areas in neurological and biomedical
15 research today. However, despite the growing breadth of AD research across institutions and
16 fields, the span of brain areas typically investigated, particularly in relation to neurofibrillary tangle
17 (NFT) pathology, has remained quite narrow. As emphasized by Braak and Braak in the early 90s
18 ¹, the transentorhinal region (TER), entorhinal cortex (ERC), and hippocampus (including
19 subiculum and cornu ammonis 1 (CA1)) are among the first areas known to be affected by NFT
20 pathology. Consequently, both imaging and histopathological studies over the last three decades
21 have focused on these regions not only with respect to classical neuropathological staging
22 guidelines ^{2, 3}, but also in studies attempting to identify early biomarkers of AD ^{4, 5} and
23 pathophysiological mechanisms of causation ⁶. Advancements in imaging technologies over the
24 last decade ⁷⁻¹⁰, however, have enabled the capture of more varied biological data (e.g. molecular
25 images) across wider spatial windows, consequently facilitating a broader scope of investigation.
26 Evidence from a number of recent imaging studies has particularly begun to suggest that the
27 amygdala (Figure 1a) might play a role complementary to the TER, ERC, and hippocampus in
28 early AD.

1
2 Here, we first review these recent imaging studies in the context of earlier work predating and
3 following Braak and Braak's historic observations ¹ to illustrate the mounting evidence of the
4 amygdala's role in AD. While not precluding the amygdala's importance as a reservoir of amyloid-
5 beta (A β) pathology, we focus, here, on the proposed role of the amygdala in NFT pathology as
6 NFT pathology has been most closely associated with neurodegeneration and cognitive decline ¹¹⁻
7 ¹⁴. (While some studies also focus on neuropil threads, for simplicity we will refer to tau pathology
8 in AD as NFT pathology.) Beginning with the late 1970s and early 1980s, we survey some of the
9 findings through the turn of the century in the area of post-mortem histopathological analysis that
10 implicate the amygdala in AD NFT pathology. We note the relative dearth of literature on the
11 amygdala in AD in the late 90s and early 2000s and consequently discuss some of the possible
12 reasons why the amygdala underwent less investigation than the TER, ERC, and hippocampus
13 during this time. Finally, we highlight the evidence that has emerged in the last years,
14 predominantly as a consequence of novel imaging technologies and analytical techniques, that is
15 rekindling interest in the amygdala and supporting its role in AD NFT pathology.

16
17 In the second half of the article, we offer further perspective on this role by linking the findings
18 surveyed in the first half both to connectivity studies and symptomatology in AD. In particular,
19 we interpret the early sites of NFT accumulation in the amygdala in light of its connectivity profile
20 obtained from the animal literature. We subsequently suggest a role for the amygdala as part of an
21 alternative pathway of NFT spreading in the medial temporal lobe (MTL), apart from that
22 classically described between regions of the ERC and hippocampus. We support the existence of
23 such a pathway, here, with novel human data. We also discuss the link between NFT accumulation
24 in the amygdala and specific (neuropsychiatric) symptomatology in AD, in light of the functional
25 associations of the amygdala and its networks.

26
27 In summary, with these novel findings and resurfacing neuropathological observations, as well as
28 the patterns of connectivity and clinical manifestations associated with the amygdala, we suggest
29 that the amygdala should play a more central role in AD, and particularly NFT-related, research in
30 the future. As its role in the symptomatology in AD and the spreading of NFT pathology continues

1 to become evident, we expect imaging measures of the amygdala to be useful biomarkers for
2 clinical trials and ultimately clinical practice.

3

4 **Historical Trajectory of the Amygdala in AD Research**

5

6 Early Evidence of the Importance of the Amygdala in AD

7 The earliest evidence of NFT pathology in the amygdala in the context of AD dates back to the
8 1970s and 1980s, in a collection of post-mortem analyses, similar to that presented by the Braaks.
9 Though often underemphasized, the Braaks, themselves, indicated the appearance of NFTs in the
10 amygdala as early as stage II, growing to moderate amounts seen in stages IV and V ¹. Their report
11 followed a boom time in the 1970s and 1980s when numerous post-mortem studies highlighted
12 the presence of NFTs in the amygdala in AD ¹⁵⁻²². While the number of cases included in these
13 reports was modest (between 10 and 48), the findings point unanimously towards the importance
14 of the amygdala as an accumulation site for NFTs in AD. A mixture of early onset versus late onset
15 AD cases were included in the different studies, and while most cases received a diagnosis of
16 dementia before death, cases in earlier clinical stages were also included. Regardless of the
17 composition of the study population, the amygdala was a clear site for NFT accumulation in all
18 studies, indicating the importance of the amygdala throughout the different clinical stages of AD.
19 Interestingly, neuron loss, as aforementioned often thought to be the result of NFT pathology ¹²,
20 ¹⁴, was also reported in the amygdala in dementia cases with AD neuropathologic change ^{19, 23}.

21

22 Diminished Focus in AD-related Research on the Amygdala Due to Methodological Challenges

23 Despite these early findings highlighting the involvement of the amygdala in NFT pathology, the
24 late 90s and early 2000s experienced a relative dearth in interest around the amygdala and
25 consequently in findings. One potential cause of this diminished focus was the desire to focus on
26 *earliest* (stage I) NFT pathology both for diagnostic purposes and to uncover the yet unknown
27 pathophysiological mechanisms of AD. Hence, despite the Braaks' observation of NFT pathology
28 in the amygdala in stage II ¹, emphasis was often placed instead on their observations of NFT
29 pathology in the hippocampus, ERC, and TER, as areas of earliest pathology. A second potential

1 cause might rest in the relative difficulty of measuring the amygdala in imaging studies, which
2 were beginning to emerge during this time. The amygdala has historically proven a more difficult
3 structure to segment, compared with the ERC and hippocampus ²⁴, and as a result, has made it less
4 conducive to manual and automatic identification and downstream analysis. Finally, the focus on
5 AD's hallmark clinical symptom of 'episodic memory loss' supports a third potential cause of
6 omission, with the hippocampus carrying functional focus in AD and the amygdala, instead, being
7 associated with neuropsychiatric symptoms and thus linked more to primary psychiatric conditions
8 such as affective disorders, and schizophrenia ²⁵⁻²⁷. Interestingly, however, it is now recognized
9 that neuropsychiatric symptoms are an early symptom, and potentially even the earliest in some
10 individuals, of AD ²⁸. We discuss the role of the amygdala in the context of these occurring
11 neuropsychiatric symptoms further in the last section.

12

13 **Emerging Evidence in Support of an Early Role for the Amygdala in AD**

14 Evidence has begun to emerge over the last 5-10 years that suggests the amygdala can be
15 repositioned as a key area for study in relation to AD. Imaging technologies and analytical
16 techniques have begun to offer scientists wider windows into neuroanatomy, facilitating the
17 emergence of findings outside the immediate focus regions of past technologies. Concurrently,
18 technologies are developing to match this spatial breadth with information depth, with both the
19 variety and resolution of measures increasing at a rapid rate. This has facilitated the study of
20 pathological measures, such as patterns of NFTs, in a larger spatial context of surrounding tissue
21 (e.g. in 3D), and the measurement of shape changes (e.g. local volume changes) on magnetic
22 resonance imaging (MRI) in particular structures with more accuracy. Together, these technologies
23 have enabled different groups to study AD from new visual and phenomenological angles, which
24 have independently highlighted an important role for the amygdala in AD.

25

26 **Post-mortem Histological 3D Reconstruction of NFT Pathology in the Amygdala**

27 One class of evidence that implicates the amygdala particularly in AD NFT pathology stems from
28 newly arising techniques to build state-of-the-art datasets with reconstructed histopathological
29 measures in the space of 3D MRI, as demonstrated both by Yushkevich et al. ²⁹ and Stouffer et al.

1 ³⁰. Such datasets offer the opportunity for investigating with both high resolution and broad spatial
2 coverage the distributions of pathology in individual subjects. Both groups report high levels of
3 NFT pathology not only in expected areas such as the TER and ERC, but also in the amygdala, in
4 cases with early ²⁹ and advanced ³¹ AD pathology. Furthermore, these 3D reconstructions of digital
5 pathology have afforded high enough resolution for both groups to observe NFT pathology
6 aggregating particularly within the inferior-medial domain of the amygdala (Figure 1b; note that
7 given the disagreement on the parcellation and nomenclature of the amygdala nuclei, we chose the
8 word “domain” to refer broadly to the different regions within the amygdala, particularly in
9 reference to localizing NFT accumulation). This spatial segregation they both report matches the
10 general trend from previous post-mortem studies that compared the location of NFT pathology in
11 specific amygdala nuclei in a 2D manner, often in single or a few slices (^{15-19, 21, 22} but note that
12 one study indicated a different pattern of NFT accumulation in the amygdala ¹).

14 *Tau-Positron emission tomography (PET) Imaging Highlights the Amygdala as a Key Region for* 15 *NFT Accumulation*

16 A second line of evidence amassing in support of the amygdala’s role in AD pathology harnesses
17 the techniques of molecular imaging, such as tau-PET, to interrogate pathological distributions in
18 vivo. Berron et. al utilized an event based modeling (EBM) approach coupled with tau-PET
19 imaging in cognitively unimpaired individuals and patients with mild cognitive impairment (MCI),
20 both A β positive, to identify the sequence of brain regions affected by NFT pathology ³². While
21 the amygdala was not included in the development of the EBM sequence, their results show strong
22 tau-PET signal in the amygdala in the earliest EBM stages (note that staging using tau-PET is not
23 synonymous to Braak staging; Figure 3). The results of Yoon et. al ³³ echo these findings with
24 highest burden of NFT pathology found in the amygdala in a group of A β positive subjects with
25 and without cognitive impairment, with both types of pathology characterized through PET
26 imaging. Similar results were found in two other cohorts with highest, or among the highest, tau-
27 PET signal in the amygdala in A β positive cognitively *unimpaired* individuals ^{34,35}, suggesting an
28 early role for the amygdala even before cognitive symptoms are observed. In addition, Insel and
29 colleagues utilized disease time as a measure of disease severity to identify brain regions with the
30 highest tau-PET uptake ³⁶. Again, the amygdala was the earliest brain region showing the highest

1 mean tau-PET uptake as early as 10 years before an AD diagnosis and even preceding the
2 appearance of NFT pathology in the ERC. Finally, Leuzy and colleagues used longitudinal tau-
3 PET to identify brain regions with the largest annual increase in tau-PET uptake³⁷. Combining an
4 EBM and a clustering approach, they sought to characterize the combination of brain regions
5 amidst 35 regions of interest that showed the largest annual increase in tau-PET uptake. For A β
6 positive cognitively unimpaired individuals, the regions showing this largest increase were the
7 ERC, the hippocampus, and the amygdala.

8 Hence, the appearance of NFT pathology in the amygdala via molecular imaging echoes
9 the distributions found post-mortem via traditional histopathological staining and consequent
10 mapping to 3D. Indeed, the correspondence between patterns observed through histopathological
11 studies and molecular imaging has also motivated efforts to utilize tau-PET as a means of
12 approximating Braak stages of individuals in vivo, where measurable NFT pathology in the
13 amygdala has been cited, for instance, in as early as Stage III³⁸. While post-mortem studies still
14 achieve higher resolutions in reported distributions of NFT pathology and sensitivity to the earliest
15 stages, the increasing availability of tau-PET as well as its use in vivo have enabled the study of
16 larger and more diverse cohorts. As manifested in the findings reported here, this, in turn, has
17 enabled both spatial and longitudinal studies of NFT pathology, which further elucidate the
18 amygdala as not just being affected by NFT pathology, but being specifically affected by NFT
19 pathology in early (preclinical and prodromal) stages of AD. This suggests that imaging measures
20 of the amygdala could be an attractive biomarker, for example, for enrichment in clinical trials or
21 for monitoring disease progression.

22 23 Amygdala Atrophy on structural MRI relates to Downstream Cognitive Impairments and 24 Neuropsychiatric Symptoms

25 A final class of growing evidence on the amygdala's role in AD is that from structural MRI
26 analysis. While MRI has the advantage of studying cohorts in vivo, most of this evidence stems
27 from studies that classified individuals according to clinical diagnoses of AD rather than those
28 determined by the presence of A β pathology according to PET or biofluid measures. As such,
29 amygdala observations associated with these studies have not typically been linked directly to
30 *biological* AD and characteristic patterns of NFT pathology. Rather, such changes have been

1 associated with clinical changes associated with AD, such as cognitive and neuropsychiatric
2 symptoms.

3 For instance, several studies showed volumetric MRI measures of the whole amygdala to
4 correlate directly with measures of memory performance or global cognition ³⁹⁻⁴². In other studies,
5 amygdala volume was either the sole or an independent predictor of performance on cognitive tests
6 when other MTL structural measures were also included in the model ⁴³⁻⁴⁵. Additionally, right
7 amygdala volume, beyond other structural brain measures, was associated with the worsening of
8 neuropsychiatric symptoms, such as agitation and aggression, in patients with cognitive
9 impairment ⁴⁵. Finally, Liu et al. ⁴⁶ found that amygdala volume was a predictor of conversion to
10 dementia.

11 Another body of evidence in structural MRI has focused not only on measurements of
12 global amygdala volume but also local shape changes in the amygdala and their link to AD. Recent
13 work from Stouffer et al. ³¹ coupled manual amygdala segmentations of longitudinal MRI scans
14 with diffeomorphometry to achieve estimates of atrophy rate per subject and across populations,
15 addressing some of the challenges that have hindered study of the amygdala previously (e.g.
16 automatic segmentation schemes and variability in image sequences over time). They showed
17 significantly higher rates of global amygdala volume loss in subjects converting to MCI or to
18 dementia of the Alzheimer's type (clinical diagnosis without biomarker confirmation) (6.8% and
19 11.6% volume loss/year, respectively) than in stable controls (1.5% volume loss/year).
20 Furthermore, they localized areas of greatest volume loss on average across subjects in each cohort
21 to the inferior-medial domain of the amygdala with least loss observed laterally. Similarly, Miller
22 et al. ⁴⁷ used diffeomorphometry to characterize finer-grained atrophy, measured at the level of
23 vertex-wise expansion or contraction in surface meshes of the amygdala, generated from
24 segmentations from MRI scans of controls versus patients with clinical dementia of the
25 Alzheimer's type. Interestingly, they, too, reported most significant atrophy in the inferior-medial
26 domain, encompassing the areas of densest NFT accumulation in post-mortem reconstructions ²⁹.
27 ³¹, with extensions laterally ⁴⁷ possibly due to NFT pathology having spread laterally in the clinical
28 stage of dementia or to other comorbid pathologies. Finally, a recent study used spherical mapping
29 also to characterize vertex-wise differences in amygdala shape measured across a population with
30 post-mortem MRI. They highlighted significant "inward deformation" (atrophy) both in the
31 inferior-medial domain with extensions laterally in individuals with AD-specific pathology ⁴⁸,

1 providing initial evidence for AD-specific localized atrophy in the amygdala. However, this study
2 was limited by linkage to semi-quantitative measures of AD pathology that represented the global
3 burden in the hemisphere rather than a local burden in the amygdala.

4 Finally, echoing the EBM approach in the tau-PET studies described above, a last line of
5 evidence in structural MRI involves the use of longitudinal MRI scans coupled with changepoint
6 temporal modeling to estimate not just *where* but *when* atrophy occurs in various areas of the MTL
7 during the course of individuals' progression from normal cognition to MCI and clinical dementia
8 of the Alzheimer's type. For instance, Miller et. al.⁴⁹ couple diffeomorphometry with changepoint
9 modeling in analyzing longitudinal MRI scans from individuals along this progression. They report
10 most significant atrophy globally within the ERC, followed by the amygdala, and then the
11 hippocampus when comparing both diseased populations to controls. Furthermore, they estimate
12 the ERC to be the structure with the earliest onset of atrophy, followed by the amygdala, and then
13 the hippocampus, highlighting amygdala atrophy as an early event in the progression to MCI and
14 ultimately clinical dementia of the Alzheimer's type.

15 Hence, in general, structural MRI has facilitated investigation and consequent
16 manifestation of changes in global amygdala volume and more local shape characteristics (e.g.
17 regional surface area contraction) that have been linked to the earliest stages of cognitive decline,
18 with a large portion of subjects progressing onto clinical dementia of the Alzheimer's type.
19 Together, this body of evidence suggests, as in the previous studies, that the amygdala may play a
20 role not just in AD, generally, but particularly in its earliest stages, amidst the onset of cognitive
21 and neuropsychiatric symptoms. Consequently, the continued study of the amygdala through
22 modes of clinical imaging such as MRI before and during the disease course will be integral both
23 to understanding and ultimately monitoring and even predicting patients' progressing AD
24 symptomatology.

25 26 **Anatomical Evidence for Amygdala-associated Tau Spread in AD**

27 The sequential emergence of NFT pathology across interconnected brain networks has led to the
28 hypothesis that NFT pathology spreads along strongly connected brain regions through a
29 connectional transmission mechanism⁵⁰. There is a wealth of in vivo human studies using
30 functional MRI (fMRI) that lend support to this (summarized in⁵¹). Studies found that NFT

1 pathology accumulates preferentially in regions that are closely connected to epicentres – regions
2 that show high levels of brain alterations in early disease stages⁵²⁻⁵⁴. Longitudinal imaging studies
3 further showed that regions that are closely connected to those epicentres show the fastest rate of
4 NFT accumulation^{55,56}. Finally, studies using subtype- or individual-specific epicentres showed
5 even improved predictive power suggesting considerable epicentre variability between individuals
6^{55,57}. However, the spreading of NFT pathology within the MTL, and in particular the role of the
7 amygdala herein, has received less attention. Hence, we here review key aspects of the amygdala's
8 and MTL's connectivity obtained from animal literature. We complement these findings by
9 presenting novel in vivo experimental data in humans using high-field fMRI. Not only do these
10 biological attributes further support the body of evidence presented above, but taken together, they
11 even suggest that the amygdala might play a unique role in NFT spreading in the MTL in early
12 AD stages.

14 *Amygdala Connectivity from Animal studies Highlights Integral Connections with Early NFT* 15 *Regions*

16 Early NFT pathology in the amygdala is not surprising when considering the connectivity pattern
17 of the amygdala. The animal literature shows that the amygdala has strong connections with other
18 brain regions that show very early NFT accumulation¹, including the locus coeruleus, the
19 perirhinal and entorhinal cortices (which include the TER), and the region of the subiculum that
20 borders with the CA1 of the hippocampus, also referred to as the prosubiculum⁵⁸⁻⁶¹ (Figure 1c).
21 Interestingly, the connections between the amygdala and the hippocampus, as documented in
22 animals, are reciprocal, and preferentially connect the anterior domain of the hippocampus with
23 the inferior-medial domain of the amygdala^{58,59,61} (Figure 2). This inferior-medial domain, as
24 discussed above, was the region found to show the densest NFT accumulation in 3D reconstruction
25 studies^{29,31} and older histopathological studies^{15-19,21,22} (Figure 1d), as well as show significant
26 atrophy in longitudinal MRI studies^{31,47}. Strikingly, the reciprocal connections with the
27 anterolateral part of the ERC are also associated with this inferior-medial amygdala domain^{58,60,}
28⁶².

29 Importantly, tracing studies in a variety of animal species have shown different amygdala
30 nuclei to have very different connections, and particularly relevant for the present article, that the

1 overall structure and organization is evolutionarily relatively preserved across these species ⁶³.
2 This suggests these connectivity patterns can be taken to hold true in humans as well. In general,
3 this connectivity pattern of the amygdala further explains early occurrence of NFT pathology in
4 not just the amygdala as a whole structure, but particularly the inferior-medial domain.

5
6 *Animal and Human Studies of Amygdala Connectivity Highlight Connections for Tau Spread to*
7 *Anterior Hippocampus*

8 The connectivity of the amygdala also seems to have implications for the occurrence of NFT
9 pathology in other MTL regions and might provide a different pathway of NFT spreading to the
10 anterior hippocampus. The anterolateral ERC and the adjacent TER have traditionally been
11 implicated as an early locus of NFT pathology ¹. (Although TER as such has never been formally
12 described in animals, it has been proposed that it represents a part of perirhinal Brodmann Area 35
13 that directly borders ERC laterally ^{64,65}. For the purpose of the following connectional summary,
14 we opt to include it into ERC.) NFT pathology in AD is also observed in hippocampal subregions
15 CA1 and subiculum early on ¹. Within the hippocampus, both the anterior and extreme posterior
16 regions seem to harbor the same level of NFT pathology, with a paucity of pathology in the middle
17 region of the hippocampus (body). This distribution of pathology appears in early stages ²⁹, but
18 has also been observed to be maintained even in advanced stages of AD ^{30,31}. Interestingly, the
19 anterolateral ERC has preferential reciprocal connections to posterior rather than anterior parts of
20 the hippocampus ⁶⁶⁻⁶⁸. Assuming a model of NFT spread through connected brain regions, the
21 occurrence of NFT pathology in the posterior hippocampus can be explained by early NFT
22 pathology in the anterolateral ERC through these preferential reciprocal connections. However,
23 the appearance of early NFT pathology in the anterior hippocampus still lacks a plausible
24 trajectory, particularly in conjunction with early NFT pathology in the ERC. As discussed above,
25 the amygdala does have strong reciprocal connections with the anterior hippocampus ^{58,59,61}.
26 Therefore, the amygdala could be hypothesized to be an additional pathway for NFT spread within
27 the MTL and potentially explain this occurrence of early pathology in the anterior hippocampal
28 region. See Figure 2 for an illustration of amygdala connectivity and early accumulation sites of
29 NFT pathology.

1 In humans, the amygdala-hippocampal functional connectivity resembles the described
2 connectivity profile derived from animal studies. A functional connectivity analysis on ultra-high
3 field 7 tesla MRI data (see Grande et al., 2022⁶⁹ and Supplementary Material 1 for methods and
4 results) revealed main functional connectivity between the amygdala and an area in the anterior
5 hippocampus at the level where the uncus separates from the rest of the hippocampus (Figure
6 3). That area extends towards dentate gyrus and CA3, but clearly covers subiculum and CA1. Thus,
7 human high-resolution functional connectivity data are in line with connectivity data from the
8 animal literature and confirm connectivity primarily between the amygdala and the anterior
9 hippocampal domain, with a focus on the border domain between CA1 and subiculum
10 (prosubiculum). Strikingly, these connectivity patterns overlap with the areas of earliest
11 accumulation of NFT pathology in the hippocampus of individuals without dementia, seen
12 primarily in the anterior domain, as outlined in Figure 3 (adapted from³²). Taken together, these
13 results further support the hypothesis of NFT pathology spreading via an amygdala-anterior
14 hippocampal route in addition to that traditionally described between the ERC and posterior
15 hippocampus.

17 *The Amygdala as an Additional Pathway of NFT Spreading: Discussion and Future Research*

18 Following a model of NFT spread via neuronal connections, the previous section introduced the
19 hypothesis of an amygdala-anterior hippocampal pathway of NFT pathology spread as a potential
20 explanation of the early appearance of NFT pathology in the anterior hippocampus. Nevertheless,
21 open questions remain around the exact timing and initial sourcing of NFT pathology with respect
22 to its appearance in the amygdala, hippocampus, and ERC. As such, there exist alternative
23 hypotheses and variations on the one presented above in which the amygdala is likely posed as a
24 source of NFT pathology that subsequently spreads to the anterior hippocampus. For instance, one
25 important question is where the NFT pathology in the amygdala is coming from; i.e. whether it
26 starts in the amygdala or comes from other early NFT regions such as the anterolateral ERC. While
27 the answer does not affect the feasibility of NFT spread from the amygdala to the anterior
28 hippocampus, the question nevertheless serves as a starting point for future research also to
29 understand the complementary roles the amygdala and ERC might play in spreading of NFT
30 pathology. Additionally, the reciprocal connections between the amygdala and anterior

1 hippocampus do not provide evidence for the directionality of potential NFT spread between these
2 two structures. Besides the amygdala, the anterior hippocampus could also serve as a starting point
3 of NFT pathology and thus initiate spread from the anterior hippocampus to the amygdala. It would
4 be unclear in this scenario where the NFT pathology in the anterior hippocampus would come
5 from; however, it is possible that the anterior hippocampus is another starting point for NFT
6 pathology in the MTL, besides the ERC-TER border region. One argument in favor of this is the
7 report of a few isolated tangles in CA1 in stage I, with those in the amygdala only reported in stage
8 II¹. It is unclear, though, how much weight can be placed on these descriptions as they were based
9 on only a few histology sections where a few isolated tangles in the amygdala may have easily
10 been missed. Regardless of the exact ordering of events, both plausible directions of spread support
11 a role for the amygdala as a vehicle of NFT spread within the MTL.

12 Establishment and further investigation of this amygdala-anterior hippocampal spread
13 fosters several new research avenues, many of which utilize the same technologies that have begun
14 to highlight the amygdala's role in AD, as discussed above. For example, longitudinal tau-PET
15 studies can be used to establish the association between tau-PET signal and accumulation in the
16 different MTL regions, where a stronger link would be expected in tau-PET uptake and
17 accumulation between the amygdala and anterior hippocampus than anterior hippocampus and
18 anterolateral ERC. This could be complemented by ultra-high field imaging studies of the
19 structural and functional connectivity patterns in these regions. Such a combinatorial approach
20 would potentially allow for establishing the role of the amygdala in spreading of NFT pathology
21 in the MTL, although it is inherently challenging to separate such small regions with the relatively
22 low resolution of PET imaging. To establish the order of occurrence of pathology within these
23 MTL regions, new statistical methods, such as EBM⁷⁰, could be utilized in tau-PET datasets and
24 ultimately as well in growing post-mortem datasets with dense NFT staining in the MTL at
25 different stages of the disease^{29, 31}.

26 A final research avenue is the investigation of whether the occurrence of such an additional
27 pathway of NFT spreading is heterogeneous between patients. Four potential distinct trajectories
28 of NFT deposition throughout the whole brain have been identified in a recent human in vivo study
29⁵⁷. The question is whether such distinct trajectories for NFT spreading also exist within the MTL,
30 with different patients typically exhibiting one of these distinct trajectories. The answer to this can
31 potentially be addressed with longitudinal tau-PET studies. Furthermore, heterogeneity in the

1 pathways of NFT spreading in the MTL could potentially explain clinical differences observed in
2 the order in which symptoms appear in patients. For instance, more prominent NFT accumulation
3 and spreading from the anterolateral ERC to the posterior hippocampus in the early stages would
4 likely give rise to memory impairments as the first symptom⁷¹, as typically reported in AD (Albert
5 et al. 2011). In contrast, more prominent NFT accumulation in and spreading through the amygdala
6 and anterior hippocampus might result in the earliest symptoms being neuropsychiatric in nature
7⁷¹, which has indeed been reported in a subset of AD patients⁷². Hence, future areas of
8 investigation rest not only in further solidifying the amygdala's role in the spread of NFT
9 pathology throughout the MTL but also establishing the link of such a role for the amygdala to
10 what we observe clinically in patients.

11

12 **Implications of Early Amygdala Involvement for AD symptomatology**

13 As the amygdala has been associated with different cognitive, emotional, and behavioral processes
14⁷³⁻⁷⁶, early NFT accumulation in the amygdala may, at least partly, explain the occurrence of
15 neuropsychiatric symptoms observed in AD^{77,78}. While NFT accumulation in the amygdala, itself,
16 may play a role, NFT accumulation across the networks connected to the amygdala may also link
17 to observed symptoms. This further underscores the important role an amygdala-anterior
18 hippocampal circuit might play in AD, as one example of an amygdala associated network. Indeed,
19 as we speculated in the previous section, early NFT spread between the amygdala and anterior
20 hippocampus may give rise to a “neuropsychiatric-symptoms-first” subtype. In this section we will
21 shortly summarize different behavioral and emotional processes the amygdala is implicated in,
22 where we will zoom in on the amygdala nuclei and their functionality and discuss the functions of
23 different amygdala networks (see⁷⁹⁻⁸¹). Subsequently, we will relate the reported functions of the
24 amygdala to neuropsychiatric symptoms observed in early AD and discuss future areas of research.

25

26 **Functionality of Amygdala Nuclei and Amygdala Associated Networks**

27 The amygdala consists of different nuclei that show striking morphological, connectional, and
28 developmental differences (Figure 1b). Interestingly, there are some indications from animal and
29 post-mortem studies supportive of a hypothesis of potential functional differentiation of the

1 different amygdala nuclei (Figure 1e). These hypotheses for functional differentiation are based
2 on ablation studies in rodents and other animals, studies on receptor density of, for example,
3 neurotransmitters in the different nuclei, and studies on observed connectivity of the amygdala
4 with other regions in animal studies. For example, the lateral, basal and central nuclei are
5 implicated in fear and stress because of a high density of benzodiazepine receptors in the first two
6 and of glucocorticoids receptors in the latter ⁷³⁻⁷⁵. Regarding feeding behavior, lesions in the
7 central, medial and cortical nuclei result in a loss of appetite or thirst whereas lesions to the
8 basolateral nucleus result in the opposite: excessive thirst or hunger. The basal, accessory basal
9 and cortical nuclei have been implicated in motivational responses and reward behavior because
10 of their direct connections with the prefrontal cortex, including orbitofrontal and medial prefrontal
11 cortices ⁷⁴. Moreover, behavioral studies in different mammals have suggested a role for the medial
12 nucleus in aggressive, sexual, and defensive behaviors ⁷⁴.

13 However, in order to understand the role of the amygdala, it is important to consider its
14 role on a circuit or network level ^{79, 82, 83}. According to well-established functional connectivity
15 networks, the amygdala is part of the anterior MTL network ^{71, 82}, which also includes the anterior
16 hippocampus, the perirhinal cortex, temporopolar cortex and lateral orbitofrontal cortex.
17 Components of the anterior MTL network including the anterior hippocampus have been
18 implicated in assessing the significance of entities ^{71, 84}, including functions such as emotional and
19 reward processing, emotional memory and social cognition ^{66, 85-88}. The amygdala is also part of a
20 network consisting of inferior basal ganglia regions, the anterior cingulate cortex and the ventral
21 tegmental area which has been implicated in anhedonia and apathy ⁸⁹. A recent detailed study by
22 Klein-Flügge and colleagues characterized functional connectivity profiles of the whole amygdala
23 as well as its subregions and investigated their relationship with four mental health dimensions -
24 life satisfaction, negative emotions, sleep problems and anger ⁸². The results suggest a role for
25 connectivity of the inferior-medial domain of the amygdala in anger and negative emotions such
26 as sadness. This association of the inferior-medial domain of the amygdala with fear and anger
27 matches what is known from animal work and reports of receptor density ⁷³⁻⁷⁵.

28 Based on this summary and given that NFT pathology has been mainly reported within the
29 inferior-medial domain in the early stages of AD, one could hypothesize that early
30 neuropsychiatric symptoms in AD that are due to NFT accumulation in the amygdala and
31 amygdala networks could include changes in motivational (e.g. apathy), aggressive and sexual

1 behavior, changes in appetite, social cognition and in processing and memory of emotional stimuli
2 as well as experiences of anger, anxiety, fear or depression.

3
4 *Linking Functionality of the Amygdala's Inferior-medial Domain and Networks to*
5 *Neuropsychiatric Symptoms Observed in Early AD*

6 In this section, we aim to link the functionality of the amygdala and associated networks to reported
7 neuropsychiatric symptoms in the early stages of AD. Neuropsychiatric symptoms are increasingly
8 recognized as an important part of the clinical profile of AD. Indeed, the first described Alzheimer
9 patient, Auguste Deter, was reported to have a range of prominent neuropsychiatric symptoms,
10 including paranoia, anxiety, apathy and aggression⁹⁰. Moreover, neuropsychiatric symptoms are
11 now recognized to be early, and in some individuals, even among the earliest symptoms, according
12 to the National Institute on Aging and Alzheimer's Association (NIA-AA) Research Framework
13²⁸.

14 Neuropsychiatric symptoms have also received renewed interest with the recently coined
15 concept of Mild Behavioral Impairment (MBI). MBI was introduced as a neurobehavioral
16 analogue to MCI to capture the range of symptoms that occur in preclinical and early symptomatic
17 AD either alongside or sometimes in advance of cognitive complaints^{91,92}. According to the
18 provisional criteria, MBI is characterized by new onset and sustained neuropsychiatric symptoms
19 that develop in advance of dementia. MBI symptoms have been reported in up to 10-15% of
20 cognitively unimpaired older individuals and to be associated with greater cognitive decline^{92,93}.
21 MBI covers neuropsychiatric symptoms such as impaired drive and motivation (apathy), emotional
22 dysregulation (mood and anxiety symptoms), impulse dyscontrol, agitation or abnormal reward
23 salience (changes in response inhibition and self-regulation), social inappropriateness (impaired
24 social cognition), and abnormal thoughts or perception (psychosis)⁹³. Some psychological
25 symptoms (e.g. anxiety) might arise as reactive psychological symptoms to the early cognitive
26 decline (i.e., coping and adjusting) and not always as sequelae of neurodegeneration^{94,95}. However,
27 these are not MBI; in this section, we consider primary neuropsychiatric symptoms, as described
28 in the setting of MBI and their possible link to pathology and neurodegeneration in the amygdala
29 and associated networks.

1 Based on the previous section (“Functionality of Amygdala Nuclei and Amygdala
2 Associated Networks), impaired drive and motivation, emotional dysregulation, social
3 inappropriateness, and perhaps agitation could be due, at least partly, to NFT accumulation in the
4 amygdala and amygdala networks. Recent evidence showing an association of MBI with tau-PET
5 signal in the MTL in cognitively unimpaired individuals is supportive of this notion and suggests
6 that MBI can be an early manifestation of underlying neurodegenerative disease in advance of
7 significant cognitive impairment ^{77, 92}. Another recent study found a relationship between increased
8 tau-PET signal in the MTL and depressive symptoms in cognitively normal older adults ⁹⁶.
9 However, neither of these studies focused on tau-PET signal in the amygdala. To the best of our
10 knowledge, only one study so far has looked at the association of neuropsychiatric symptoms and
11 amygdala tau-PET uptake and did not find an association ⁹⁷. However, as this was an analysis in
12 the Alzheimer’s Disease NeuroImaging Initiative (ADNI) dataset, the results should be interpreted
13 with caution as ADNI has restrictive inclusion criteria around mental health symptoms. Moreover,
14 this study used the Neuropsychiatric Inventory, which is designed primarily to assess the spectrum
15 of symptoms observed in dementia and not in earlier stages, such as the MBI Checklist ⁹⁸. Hence,
16 studies designed a priori to examine NFT pathology in the amygdala related to MBI are needed to
17 definitely and robustly link these phenomena.

18 Overall, there is a growing literature on the occurrence of neuropsychiatric symptoms in
19 early AD that, strikingly, match the majority of the neuropsychiatric symptoms expected to follow
20 from NFT accumulation in the amygdala. However, this observation is mostly circumstantial and
21 requires direct linkage through neuroimaging studies of the amygdala, as discussed further in the
22 next section.

24 *Future Directions for Studying the Role of the Amygdala in Neuropsychiatric Symptoms of AD*

25 The aforementioned literature suggests a role for the amygdala and its associated networks in
26 neuropsychiatric symptoms. However, much work is still needed to solidify and understand fully
27 the association of NFT pathology in the amygdala and its associated networks and specific
28 neuropsychiatric symptoms in AD. In addition to supporting these findings with similar methods
29 applied to additional cohorts, future research avenues include the analysis of tau-PET imaging in
30 relation to different neuropsychiatric symptoms, the study of comorbid pathologies (co-

1 pathologies) in the amygdala as alternative or complementary causes of neuropsychiatric
2 symptoms, and the development of novel fMRI paradigms for analyzing specific neuropsychiatric
3 alterations against changes in specific nuclei of the amygdala or specific amygdala networks.

4 For instance, correlation of different symptoms with amygdala tau-PET signal could
5 further solidify the specific link between neuropsychiatric symptoms and NFT accumulation in the
6 amygdala and associated networks in AD. Based on the above literature, one would expect changes
7 in social cognition, apathy, anger, aggression, irritability, anxiety and depression, and sexual and
8 eating behavior to associate specifically with tau-PET signal in the amygdala (and associated
9 networks) when occurring in the early stages of AD.

10 Secondly, the amygdala has been cited not just as a hotspot for NFT pathology, but also of
11 alpha-synuclein (the protein that accumulates in Lewy bodies and neurites) and transactive
12 response DNA-protein (TDP) 43 pathology in AD⁹⁹⁻¹⁰¹ (see Supplementary Material 2 for a
13 review of the literature on the distribution pattern of these co-pathologies in the amygdala). This
14 thus indicates that the role other co-pathologies in the amygdala play in the development of
15 neuropsychiatric symptoms should also be explored. For instance, alpha-synuclein pathology in
16 the amygdala has been linked to visual hallucinations¹⁰²⁻¹⁰⁴. While these studies were not
17 performed in cases with AD, Lewy body pathology often co-occurs in AD in the amygdala<sup>99, 105-
18 108</sup>, and could potentially contribute to the occurrence of such symptoms. Interestingly, comorbid
19 Lewy body pathology in the amygdala in AD has also been linked to depressive symptoms¹⁰⁹.
20 While there are no PET measures for alpha-synuclein pathology yet, promising cerebrospinal fluid
21 measures are currently under development^{110, 111}. A future avenue of research would be to
22 investigate if cerebrospinal fluid measures of alpha-synuclein pathology, as a comorbid pathology,
23 mediates a potential association between amygdala atrophy and depressive symptoms and
24 hallucinations in the context of AD. Relatedly, it would be of interest to gain a better understanding
25 of the role of comorbid TDP-43 pathology in the amygdala in the context of AD in the development
26 of neuropsychiatric symptoms. Previous studies looking at the association of comorbid TDP-43
27 pathology with neuropsychiatric symptoms in patients with AD neuropathologic changes showed
28 inconsistent results¹¹²⁻¹¹⁴. Future studies are needed to investigate what role TDP-43 pathology in
29 the amygdala plays in the symptom profile of AD. Moreover, while not the focus of this review,
30 the role of A β pathology, separate from NFT pathology, in the amygdala and associated networks
31 in the development of neuropsychiatric symptoms should be further explored.

1 Finally, gaining a better understanding of the functional differentiation of the nuclei could
2 lead to a better understanding of the symptomatology in AD. However, research on the functional
3 differentiation of amygdala subregions is still sparse and is usually not performed in living humans
4 (but see ⁸²). In addition, amygdala nuclei are highly intertwined which makes it inherently difficult
5 to differentiate their functionality. Nevertheless, the pace of recent developments in ultra-high field
6 imaging shows promise for elucidating the role of these different amygdala nuclei further ^{81, 115}. In
7 light of the evidence summarized here, these developments may thus foster, in parallel, intriguing
8 new research avenues linking neuropsychiatric symptoms to amygdala shape changes in early AD
9 stages, which could be hypothesized to be localized to the inferior-medial domain of the amygdala,
10 as reported in previous studies measuring shape change in the context of cognitive changes ^{31, 47}.
11 Another fascinating research avenue would focus on the development of new experimental fMRI
12 paradigms that can probe neuropsychiatric alterations specific to amygdala changes in AD. Indeed,
13 studies have linked emotional memory changes, probed with experimental paradigms, to amygdala
14 structure in the context of clinical (not biomarker confirmed) dementia of the Alzheimer's type ¹¹⁶.
15 ¹¹⁷. These could be promising paradigms for studies with patients in early AD stages, where the
16 use of ultra-high field 7 tesla fMRI could potentially further allow us to spatially pinpoint the
17 activation within the amygdala. Combining this with tau-PET imaging could provide even further
18 insight into the role of AD pathology in potential changes in emotional memory. Future studies
19 should, however, go beyond emotional memory and develop fMRI paradigms for other
20 neuropsychiatric alterations.

21

22 **Conclusion**

23 More than three decades after the paramount studies of Braak and Braak, AD still harbors
24 uncertainties with regard to its causes, mechanism, and progression. As presented here, a body of
25 evidence of early NFT pathology in the amygdala is emerging, echoing earlier post-mortem
26 findings. Together with the amygdala's anatomical connectivity with areas of the ERC and anterior
27 hippocampus and its association with neuropsychiatric symptoms observed in the clinical course
28 of AD, this evidence suggests the amygdala has a yet uncovered role in AD and, therefore, should
29 be a greater focus in AD-related research. Indeed, the results from imaging studies point to the
30 utility of amygdala imaging biomarkers for enrichment in clinical trials, for monitoring disease

1 progression, or even for prognosis. The presented overview on amygdala connectivity, patterns of
2 pathology accumulation, and functional architecture provide new insights into the mechanisms
3 behind NFT pathology progression and symptom onset in AD. It also generates new hypotheses
4 of how to explain different symptom profiles in AD, for example of the “neuropsychiatric-
5 symptoms-first” subtype, and to capture specific amygdala-focused vulnerabilities using
6 functional imaging. Moreover, the amygdala as a potential second pathway of NFT spreading in
7 the MTL provides future avenues of research by allowing for better modeling and understanding
8 of NFT spread and the heterogeneity of NFT accumulation in the MTL, which will ultimately bring
9 us one step further towards precision medicine in AD.

11 **Acknowledgements**

12 The authors thank Anika Wuestefeld for assistance with Figure 1.

14 **Funding**

15 This work is supported by grants from the Swedish Research Council (2022-00900) and the
16 Crafoord Foundation (LW). This study is supported by MultiPark - A Strategic Research Area at
17 Lund University (LW). This work is supported by the National Institutes of Health: U19-
18 AG033655, P30-AG066507, P41-EB031771, R01-EB020062, T32-GM13677, U19-MH114821,
19 R01-NS074980-10S1, RF1MH126732, RF1MH128875, F30AG077736 (MM and KS) and the
20 Kavli Neuroscience Discovery Institute (MM and KS) as well as the Kavli Foundation and the
21 KG. Jebsen Foundation (MPW). This work is further supported by the Elly Bergren Foundation
22 and regional research support by the Division of Psychiatry, Habilitation and Medical aid, Region
23 Skåne (MJ). This work was partly supported by the National Institute for Health and Care Research
24 Exeter Biomedical Research Centre. The views expressed are those of the author(s) and not
25 necessarily those of the NIHR or the Department of Health and Social Care. This work is supported
26 by the Human Brain Project (European Union’s Horizon 2020 research and Innovation Program
27 under specific grant agreement No. 945539 (SGA3, WP 2, Task 2.1, SGA3, WP 1, Task 1.3) (ED).

1 **Competing interests**

2 Under a license agreement between AnatomyWorks and the Johns Hopkins University, Dr. Miller
3 and the University are entitled to royalty distributions related to technology described in the study
4 discussed in this. Dr. Miller is a founder of and holds equity in AnatomyWorks. This arrangement
5 has been reviewed and approved by the Johns Hopkins University in accordance with its conflict
6 of interest policies. The remaining authors declare no conflicts of interest.

7
8 **Supplementary material**

9 Supplementary material is available at *Brain* online.

10
11 **References:**

- 12 1. Braak H, Braak E. Neuropathological staging of alzheimer-related changes. *Acta Neuropathol*
13 1991;82:239-259.
- 14 2. Braak H, Alafuzoff I, Arzberger T, Kretschmar H, Del Tredici K. Staging of alzheimer disease-
15 associated neurofibrillary pathology using paraffin sections and immunocytochemistry. *Acta*
16 *Neuropathol* 2006;112:389-404.
- 17 3. Hyman BT, Phelps CH, Beach TG, et al. National institute on aging-alzheimer's association
18 guidelines for the neuropathologic assessment of alzheimer's disease. *Alzheimers Dement*
19 2012;8:1-13.
- 20 4. Wolk DA, Das SR, Mueller SG, Weiner MW, Yushkevich PA, Alzheimer's Disease
21 Neuroimaging Initiative. Medial temporal lobe subregional morphometry using high resolution
22 MRI in alzheimer's disease. *Neurobiol Aging* 2017;49:204-213.
- 23 5. Kulason S, Tward DJ, Brown T, et al. Cortical thickness atrophy in the transentorhinal cortex
24 in mild cognitive impairment. *NeuroImage: Clinical* 2019;21:101617.
- 25 6. Jagust W. Imaging the evolution and pathophysiology of alzheimer disease. *Nature Reviews*
26 *Neuroscience* 2018;19:687-700.

- 1 7. Tournier JD, Mori S, Leemans A. Diffusion tensor imaging and beyond. *Magn Reson Med*
2 2011;65:1532-1556.
- 3 8. Leuzy A, Chiotis K, Lemoine L, Gillberg P, Almkvist O, Rodriguez-Vieitez E, Nordberg A.
4 Tau PET imaging in neurodegenerative tauopathies—still a challenge. *Mol Psychiatry*
5 2019;24:1112-1134.
- 6 9. Moseley ME, Liu C, Rodriguez S, Brosnan T. Advances in magnetic resonance neuroimaging.
7 *Neurol Clin* 2009;27:1-19.
- 8 10. Villemagne VL, Doré V, Burnham SC, Masters CL, Rowe CC. Imaging tau and amyloid- β
9 proteinopathies in alzheimer disease and other conditions. *Nature Reviews Neurology*
10 2018;14:225-236.
- 11 11. Nelson PT, Alafuzoff I, Bigio EH, et al. Correlation of alzheimer disease neuropathologic
12 changes with cognitive status: A review of the literature. *Journal of Neuropathology &*
13 *Experimental Neurology* 2012;71:362-381.
- 14 12. Gomez-Isla T, Hollister R, West H, et al. Neuronal loss correlates with but exceeds
15 neurofibrillary tangles in alzheimer's disease. *Ann Neurol* 1997;41:17-24.
- 16 13. Giannakopoulos P, Von Gunten A, Kövari E, Gold G, Herrmann FR, Hof PR, Bouras C.
17 Stereological analysis of neuropil threads in the hippocampal formation: Relationships with
18 alzheimer's disease neuronal pathology and cognition. *Neuropathol Appl Neurobiol* 2007;33:334-
19 343.
- 20 14. Giannakopoulos P, Herrmann FR, Bussière T, et al. Tangle and neuron numbers, but not
21 amyloid load, predict cognitive status in alzheimer's disease. *Neurology* 2003;60:1495-1500.
- 22 15. Brady DR, Mufson EJ. Amygdaloid pathology in alzheimer's disease: Qualitative and
23 quantitative analysis. *Dement Geriatr Cogn Disord* 1990;1:5-17.
- 24 16. Hooper MW, MW H. The limbic system in alzheimer's disease. A neuropathologic
25 investigation. 1976.
- 26 17. Jamada M, Mehraein P. Verteilungsmuster der senilen veränderungen im gehirn. *Archiv für*
27 *Psychiatrie und Nervenkrankheiten* 1968;211:308-324.

- 1 18. Price JL, Davis PB, Morris JC, White DL. The distribution of tangles, plaques and related
2 immunohistochemical markers in healthy aging and alzheimer's disease. *Neurobiol Aging*
3 1991;12:295-312.
- 4 19. Tsuchiya K, Kosaka K. Neuropathological study of the amygdala in presenile alzheimer's
5 disease. *J Neurol Sci* 1990;100:165-173.
- 6 20. Unger JW, Lapham LW, McNeill TH, Eskin TA, Hamill RW. The amygdala in alzheimer's
7 disease: Neuropathology and alz 50 immunoreactivity. *Neurobiol Aging* 1991;12:389-399.
- 8 21. Kromer Vogt LJ, Hyman BT, Van Hoesen GW, Damasio AR. Pathological alterations in the
9 amygdala in alzheimer's disease. *Neuroscience* 1990;37:377-385.
- 10 22. Corsellis J. The limbic areas in alzheimer's disease and in other conditions associated with
11 dementia. Presented at the Ciba Foundation Symposium-Alzheimer's Disease and Related
12 Conditions; 1970; .
- 13 23. Scott SA, DeKosky ST, Scheff SW. Volumetric atrophy of the amygdala in alzheimer's
14 disease: Quantitative serial reconstruction. *Neurology* 1991;41:351-356.
- 15 24. Jack CR, Jr, Petersen RC, Xu YC, et al. Medial temporal atrophy on MRI in normal aging and
16 very mild alzheimer's disease. *Neurology* 1997;49:786-794.
- 17 25. Aleman A, Kahn RS. Strange feelings: Do amygdala abnormalities dysregulate the emotional
18 brain in schizophrenia? *Prog Neurobiol* 2005;77:283-298.
- 19 26. Drevets WC. Neuroimaging abnormalities in the amygdala in mood disorders. *Ann N Y Acad*
20 *Sci* 2003;985:420-444.
- 21 27. Shin LM, Rauch SL, Pitman RK. Amygdala, medial prefrontal cortex, and hippocampal
22 function in PTSD. *Ann N Y Acad Sci* 2006;1071:67-79.
- 23 28. Jack Jr CR, Bennett DA, Blennow K, et al. NIA-AA research framework: Toward a biological
24 definition of alzheimer's disease. *Alzheimer's & Dementia* 2018;14:535-562.
- 25 29. Yushkevich PA, Muñoz López M, Iñiguez de Onzoño Martin, María Mercedes, et al. Three-
26 dimensional mapping of neurofibrillary tangle burden in the human medial temporal lobe. *Brain*
27 2021;144:2784-2797.

- 1 30. Stouffer KM, Witter MP, Tward DJ, Miller MI. Projective diffeomorphic mapping of
2 molecular digital pathology with tissue MRI. *Communications Engineering* 2022;1:44.
- 3 31. Stouffer KM, Chen C, Kulason S, et al. Early amygdala and hippocampal atrophy linked to 3d
4 reconstruction of rostral neurofibrillary tau tangle pathology in alzheimer's disease. *NeuroImage:*
5 *Clinical* 2023;38:103374.
- 6 32. Berron D, Vogel JW, Insel PS, et al. Early stages of tau pathology and its associations with
7 functional connectivity, atrophy and memory. *Brain* 2021;144:2771-2783.
- 8 33. Yoon B, Guo T, Provost K, et al. Abnormal tau in amyloid PET negative individuals. *Neurobiol*
9 *Aging* 2022;109:125-134.
- 10 34. Schultz SA, Gordon BA, Mishra S, et al. Widespread distribution of tauopathy in preclinical
11 alzheimer's disease. *Neurobiol Aging* 2018;72:177-185.
- 12 35. Lowe VJ, Wiste HJ, Senjem ML, et al. Widespread brain tau and its association with ageing,
13 braak stage and alzheimer's dementia. *Brain* 2018;141:271-287.
- 14 36. Insel PS, Mormino EC, Aisen PS, Thompson WK, Donohue MC. Neuroanatomical spread of
15 amyloid β and tau in alzheimer's disease: Implications for primary prevention. *Brain*
16 *Communications* 2020;2:fcaa007.
- 17 37. Leuzy A, Smith R, Cullen NC, et al. Biomarker-based prediction of longitudinal tau positron
18 emission tomography in alzheimer disease. *JAMA neurology* 2022;79:149-158.
- 19 38. Therriault J, Pascoal TA, Lussier FZ, et al. Biomarker modeling of alzheimer's disease using
20 PET-based braak staging. *Nature Aging* 2022;2:526-535.
- 21 39. Goerlich KS, Votinov M, Dicks E, Ellendt S, Csukly G, Habel U. Neuroanatomical and
22 neuropsychological markers of amnesic MCI: A three-year longitudinal study in individuals
23 unaware of cognitive decline. *Frontiers in aging neuroscience* 2017;9:34.
- 24 40. Poulin SP, Dautoff R, Morris JC, Barrett LF, Dickerson BC, Alzheimer's Disease
25 Neuroimaging Initiative. Amygdala atrophy is prominent in early alzheimer's disease and relates
26 to symptom severity. *Psychiatry Res* 2011;194:7-13.
- 27 41. Roh JH, Qiu A, Seo SW, et al. Volume reduction in subcortical regions according to severity
28 of alzheimer's disease. *J Neurol* 2011;258:1013-1020.

- 1 42. Horinek D, Petrovický P, Hort J, et al. Amygdalar volume and psychiatric symptoms in
2 alzheimer's disease: An MRI analysis. *Acta Neurol Scand* 2006;113:40-45.
- 3 43. Mizuno K, Wakai M, Takeda A, Sobue G. Medial temporal atrophy and memory impairment
4 in early stage of alzheimer's disease: An MRI volumetric and memory assessment study. *J Neurol*
5 *Sci* 2000;173:18-24.
- 6 44. Mori E, Yoneda Y, Yamashita H, Hirono N, Ikeda M, Yamadori A. Medial temporal structures
7 relate to memory impairment in alzheimer's disease: An MRI volumetric study. *Journal of*
8 *Neurology, Neurosurgery & Psychiatry* 1997;63:214-221.
- 9 45. Trzepacz PT, Yu P, Bhamidipati PK, et al. Frontolimbic atrophy is associated with agitation
10 and aggression in mild cognitive impairment and alzheimer's disease. *Alzheimer's & Dementia*
11 2013;9:S95-S104. e1.
- 12 46. Liu Y, Paajanen T, Zhang Y, et al. Analysis of regional MRI volumes and thicknesses as
13 predictors of conversion from mild cognitive impairment to alzheimer's disease. *Neurobiol Aging*
14 2010;31:1375-1385.
- 15 47. Miller MI, Younes L, Ratnanather JT, et al. Amygdalar atrophy in symptomatic alzheimer's
16 disease based on diffeomorphometry: The BIOCARD cohort. *Neurobiol Aging* 2015;36 Suppl
17 1:S3-S10.
- 18 48. Makkinejad N, Schneider JA, Yu J, et al. Associations of amygdala volume and shape with
19 transactive response DNA-binding protein 43 (TDP-43) pathology in a community cohort of older
20 adults. *Neurobiol Aging* 2019;77:104-111.
- 21 49. Miller MI, Ratnanather JT, Tward DJ, et al. Network neurodegeneration in alzheimer's disease
22 via MRI based shape diffeomorphometry and high-field atlasing. *Frontiers in bioengineering and*
23 *biotechnology* 2015;3:54.
- 24 50. Saper CB, Wainer BH, German DC. Axonal and transneuronal transport in the transmission of
25 neurological disease: Potential role in system degenerations, including alzheimer's disease.
26 *Neuroscience* 1987;23:389-398.
- 27 51. Vogel JW, Corriveau-Lecavalier N, Franzmeier N, et al. Connectome-based modelling of
28 neurodegenerative diseases: Towards precision medicine and mechanistic insight. *Nature Reviews*
29 *Neuroscience* 2023:1-20.

- 1 52. Adams JN, Maass A, Harrison TM, Baker SL, Jagust WJ. Cortical tau deposition follows
2 patterns of entorhinal functional connectivity in aging. *Elife* 2019;8:e49132.
- 3 53. Vogel JW, Iturria-Medina Y, Strandberg OT, Smith R, Levitis E, Evans AC, Hansson O.
4 Spread of pathological tau proteins through communicating neurons in human alzheimer's disease.
5 *Nature communications* 2020;11:2612.
- 6 54. Lee WJ, Brown JA, Kim HR, et al. Regional a β -tau interactions promote onset and acceleration
7 of alzheimer's disease tau spreading. *Neuron* 2022;110:1932-1943. e5.
- 8 55. Franzmeier N, Dewenter A, Frontzkowski L, et al. Patient-centered connectivity-based
9 prediction of tau pathology spread in alzheimer's disease. *Science advances* 2020;6:eabd1327.
- 10 56. Franzmeier N, Neitzel J, Rubinski A, et al. Functional brain architecture is associated with the
11 rate of tau accumulation in alzheimer's disease. *Nature communications* 2020;11:347.
- 12 57. Vogel JW, Young AL, Oxtoby NP, et al. Four distinct trajectories of tau deposition identified
13 in alzheimer's disease. *Nat Med* 2021;27:871-881.
- 14 58. Aggleton JP. A description of the amygdalo-hippocampal interconnections in the macaque
15 monkey. *Experimental brain research* 1986;64:515-526.
- 16 59. Saunders RC, Rosene DL, Van Hoesen GW. Comparison of the efferents of the amygdala and
17 the hippocampal formation in the rhesus monkey: II. reciprocal and non-reciprocal connections. *J*
18 *Comp Neurol* 1988;271:185-207.
- 19 60. Pitkänen A, Pikkariainen M, Nurminen N, Ylinen A. Reciprocal connections between the
20 amygdala and the hippocampal formation, perirhinal cortex, and postrhinal cortex in rat: A review.
21 *Ann N Y Acad Sci* 2000;911:369-391.
- 22 61. McDonald AJ, Mott DD. Functional neuroanatomy of amygdalohippocampal interconnections
23 and their role in learning and memory. *J Neurosci Res* 2017;95:797-820.
- 24 62. Witter MP, Groenewegen HJ, Da Silva FL, Lohman A. Functional organization of the extrinsic
25 and intrinsic circuitry of the parahippocampal region. *Prog Neurobiol* 1989;33:161-253.
- 26 63. Równiak M, Bogus-Nowakowska K. The amygdala of the common shrew, guinea pig, rabbit,
27 fox and pig: Five flavours of the mammalian amygdala as a consequence of clade-specific mosaic-
28 like evolution. *J Anat* 2020;236:891-905.

- 1 64. Braak H, Braak E. On areas of transition between entorhinal allocortex and temporal isocortex
2 in the human brain. normal morphology and lamina-specific pathology in alzheimer's disease. *Acta*
3 *Neuropathol* 1985;68:325-332.
- 4 65. Insausti R, Muñoz-López M, Insausti AM, Artacho-Pérula E. The human periallocortex: Layer
5 pattern in presubiculum, parasubiculum and entorhinal cortex. A review. *Front Neuroanat*
6 2017;11:84.
- 7 66. Strange BA, Witter MP, Lein ES, Moser EI. Functional organization of the hippocampal
8 longitudinal axis. *Nature Reviews Neuroscience* 2014;15:655-669.
- 9 67. Witter MP, Amaral DG. Entorhinal cortex of the monkey: V. projections to the dentate gyrus,
10 hippocampus, and subicular complex. *J Comp Neurol* 1991;307:437-459.
- 11 68. Witter MP, Amaral DG. The entorhinal cortex of the monkey: VI. organization of projections
12 from the hippocampus, subiculum, presubiculum, and parasubiculum. *J Comp Neurol*
13 2021;529:828-852.
- 14 69. Grande X, Sauvage MM, Becke A, Düzel E, Berron D. Transversal functional connectivity
15 and scene-specific processing in the human entorhinal-hippocampal circuitry. *Elife*
16 2022;11:10.7554/eLife.76479.
- 17 70. Young AL, Oxtoby NP, Daga P, et al. A data-driven model of biomarker changes in sporadic
18 alzheimer's disease. *Brain* 2014;137:2564-2577.
- 19 71. Ranganath C, Ritchey M. Two cortical systems for memory-guided behaviour. *Nature Reviews*
20 *Neuroscience* 2012;13:713-726.
- 21 72. Wise EA, Rosenberg PB, Lyketsos CG, Leoutsakos J. Time course of neuropsychiatric
22 symptoms and cognitive diagnosis in national alzheimer's coordinating centers volunteers.
23 *Alzheimers Dement (Amst)* 2019;11:333-339.
- 24 73. Price JL, Russchen FT, Amaral DG, Björklund A, Hökfelt T, Swanson LW. *Handbook of*
25 *Chemical Neuroanatomy*, Vol 5 ed. Amsterdam: Elsevier; 1987.
- 26 74. Yilmazer-Hanke DM. Chapter 22 - amygdala. In: Jürgen K. MaiGeorge Paxinos, editor. *The*
27 *Human Nervous System (Third Edition)*. San Diego: Academic Press; 2012:759-834.

- 1 75. Rasia-Filho AA, Londero RG, Achaval M. Functional activities of the amygdala: An overview.
2 J Psychiatry Neurosci 2000;25:14-23.
- 3 76. Pessoa L. A network model of the emotional brain. Trends Cogn Sci 2017;21:357-371.
- 4 77. Johansson M, Stomrud E, Insel PS, et al. Mild behavioral impairment and its relation to tau
5 pathology in preclinical alzheimer's disease. Transl Psychiatry 2021;11:76-z.
- 6 78. Matuskova V, Ismail Z, Nikolai T, et al. Mild behavioral impairment is associated with atrophy
7 of entorhinal cortex and hippocampus in a memory clinic cohort. Front Aging Neurosci
8 2021;13:643271.
- 9 79. Benarroch EE. The amygdala: Functional organization and involvement in neurologic
10 disorders. Neurology 2015;84:313-324.
- 11 80. Janak PH, Tye KM. From circuits to behaviour in the amygdala. Nature 2015;517:284-292.
- 12 81. Kirstein CF, Güntürkün O, Ocklenburg S. Ultra-high field imaging of the amygdala - A
13 narrative review. Neurosci Biobehav Rev 2023:105245.
- 14 82. Klein-Flügge MC, Jensen DEA, Takagi Y, Priestley L, Verhagen L, Smith SM, Rushworth
15 MFS. Relationship between nuclei-specific amygdala connectivity and mental health dimensions
16 in humans. Nat Hum Behav 2022;6:1705-1722.
- 17 83. Pessoa L. How many brain regions are needed to elucidate the neural bases of fear and anxiety?
18 Neurosci Biobehav Rev 2023;146:105039.
- 19 84. Barnett AJ, Reilly W, Dimsdale-Zucker HR, Mizrak E, Reagh Z, Ranganath C. Intrinsic
20 connectivity reveals functionally distinct cortico-hippocampal networks in the human brain. PLoS
21 Biol 2021;19:e3001275.
- 22 85. Bannerman DM, Rawlins JNP, McHugh SB, et al. Regional dissociations within the
23 hippocampus--memory and anxiety. Neurosci Biobehav Rev 2004;28:273-283.
- 24 86. Fanselow MS, Dong H. Are the dorsal and ventral hippocampus functionally distinct
25 structures? Neuron 2010;65:7-19.
- 26 87. Poppenk J, Evensmoen HR, Moscovitch M, Nadel L. Long-axis specialization of the human
27 hippocampus. Trends Cogn Sci 2013;17:230-240.

- 1 88. Murty VP, Ritchey M, Adcock RA, LaBar KS. fMRI studies of successful emotional memory
2 encoding: A quantitative meta-analysis. *Neuropsychologia* 2010;48:3459-3469.
- 3 89. Husain M, Roiser JP. Neuroscience of apathy and anhedonia: A transdiagnostic approach.
4 *Nature Reviews Neuroscience* 2018;19:470-484.
- 5 90. Alzheimer A. Uber einen eigenartigen schweren erkrankungsprozess der hirinde.
6 *Neurologisches Centralblat* 1906:1134.
- 7 91. Ismail Z, Smith EE, Geda Y, et al. Neuropsychiatric symptoms as early manifestations of
8 emergent dementia: Provisional diagnostic criteria for mild behavioral impairment. *Alzheimers*
9 *Dement* 2016;12:195-202.
- 10 92. Creese B, Ismail Z. Mild behavioral impairment: Measurement and clinical correlates of a
11 novel marker of preclinical alzheimer's disease. *Alzheimers Res Ther* 2022;14:2-7.
- 12 93. Creese B, Brooker H, Ismail Z, et al. Mild behavioral impairment as a marker of cognitive
13 decline in cognitively normal older adults. *Am J Geriatr Psychiatry* 2019;27:823-834.
- 14 94. Jessen F, Amariglio RE, van Boxtel M, et al. A conceptual framework for research on
15 subjective cognitive decline in preclinical alzheimer's disease. *Alzheimers Dement* 2014;10:844-
16 852.
- 17 95. Jessen F, Amariglio RE, Buckley RF, et al. The characterisation of subjective cognitive
18 decline. *Lancet Neurol* 2020;19:271-278.
- 19 96. Gatchel JR, Donovan NJ, Locascio JJ, et al. Depressive symptoms and tau accumulation in the
20 inferior temporal lobe and entorhinal cortex in cognitively normal older adults: A pilot study. *J*
21 *Alzheimers Dis* 2017;59:975-985.
- 22 97. De Lucia N, Carbone G, Muzii B, et al. Neuropsychiatric symptoms and their neural correlates
23 in individuals with mild cognitive impairment. *Int Psychogeriatr* 2023:1-10.
- 24 98. Ismail Z, Agüera-Ortiz L, Brodaty H, et al. The mild behavioral impairment checklist (MBI-
25 C): A rating scale for neuropsychiatric symptoms in pre-dementia populations. *J Alzheimer's Dis*
26 2017;56:929-938.
- 27 99. Uchikado H, Lin WL, DeLucia MW, Dickson DW. Alzheimer disease with amygdala lewy
28 bodies: A distinct form of alpha-synucleinopathy. *J Neuropathol Exp Neurol* 2006;65:685-697.

- 1 100. Nelson P, Dickson D, Trojanowski J, et al. Limbic-predominant age-related TDP-43
2 encephalopathy (LATE): Consensus working group report. *Brain* 2019;142:1503-1527.
- 3 101. Nelson PT, Abner EL, Patel E, et al. The amygdala as a locus of pathologic misfolding in
4 neurodegenerative diseases. *J Neuropathol Exp Neurol* 2017;77:2-20.
- 5 102. Kalaitzakis ME, Christian LM, Moran LB, Graeber MB, Pearce R, Gentleman SM. Dementia
6 and visual hallucinations associated with limbic pathology in parkinson's disease. *Parkinsonism
7 Relat Disord* 2009;15:196-204.
- 8 103. Harding AJ, Stimson E, Henderson JM, Halliday GM. Clinical correlates of selective
9 pathology in the amygdala of patients with parkinson's disease. *Brain* 2002;125:2431-2445.
- 10 104. Harding AJ, Broe GA, Halliday GM. Visual hallucinations in lewy body disease relate to
11 lewy bodies in the temporal lobe. *Brain* 2002;125:391-403.
- 12 105. Hamilton RL. Lewy bodies in alzheimer's disease: A neuropathological review of 145 cases
13 using alpha-synuclein immunohistochemistry. *Brain Pathol* 2000;10:378-384.
- 14 106. Toledo JB, Gopal P, Raible K, et al. Pathological α -synuclein distribution in subjects with
15 coincident alzheimer's and lewy body pathology. *Acta Neuropathol* 2016;131:393-409.
- 16 107. Arai Y, Yamazaki M, Mori O, Muramatsu H, Asano G, Katayama Y. A-synuclein-positive
17 structures in cases with sporadic alzheimer's disease: Morphology and its relationship to tau
18 aggregation. *Brain Res* 2001;888:287-296.
- 19 108. Mikolaenko I, Pletnikova O, Kawas CH, O'Brien R, Resnick SM, Crain B, Troncoso JC.
20 Alpha-synuclein lesions in normal aging, parkinson disease, and alzheimer disease: Evidence from
21 the baltimore longitudinal study of aging (BLSA). *J Neuropathol Exp Neurol* 2005;64:156-162.
- 22 109. Lopez OL, Becker JT, Sweet RA, Martin-Sanchez FJ, Hamilton RL. Lewy bodies in the
23 amygdala increase risk for major depression in subjects with alzheimer disease. *Neurology*
24 2006;67:660-665.
- 25 110. Fairfoul G, McGuire LI, Pal S, et al. Alpha-synuclein RT-QuIC in the CSF of patients with
26 alpha-synucleinopathies. *Ann Clin Transl Neurol* 2016;3:812-818.
- 27 111. Hall S, Orrù CD, Serrano GE, et al. Performance of α Synuclein RT-QuIC in relation to
28 neuropathological staging of lewy body disease. *Acta Neuropathol Commun* 2022;10:90-7.

- 1 112. Bayram E, Shan G, Cummings JL. Associations between comorbid TDP-43, lewy body
2 pathology, and neuropsychiatric symptoms in alzheimer's disease. *J Alzheimer's Dis* 2019;69:953-
3 961.
- 4 113. Gauthreaux KM, Teylan MA, Katsumata Y, et al. Limbic-predominant age-related TDP-43
5 encephalopathy: Medical and pathologic factors associated with comorbid hippocampal sclerosis.
6 *Neurology* 2022.
- 7 114. Liu KY, Reeves S, McAleese KE, Attems J, Francis P, Thomas A, Howard R.
8 Neuropsychiatric symptoms in limbic-predominant age-related TDP-43 encephalopathy and
9 alzheimer's disease. *Brain* 2020;143:3842-3849.
- 10 115. Dumoulin SO, Fracasso A, van der Zwaag W, Siero JCW, Petridou N. Ultra-high field MRI:
11 Advancing systems neuroscience towards mesoscopic human brain function. *Neuroimage*
12 2018;168:345-357.
- 13 116. Perrin M, Henaff M, Padovan C, Faillenot I, Merville A, Krolak-Salmon P. Influence of
14 emotional content and context on memory in mild alzheimer's disease. *J Alzheimers Dis*
15 2012;29:817-826.
- 16 117. Guzmán-Vélez E, Warren DE, Feinstein JS, Bruss J, Tranel D. Dissociable contributions of
17 amygdala and hippocampus to emotion and memory in patients with alzheimer's disease.
18 *Hippocampus* 2016;26:727-738.
- 19
20

1 **FIGURE LEGENDS**

2 **Figure 1 An overview of structural, connectional and functional aspects of the amygdala. A.**
 3 Position of the amygdala in the anterior medial temporal lobe. **B.** Different nuclei in the amygdala.
 4 **C.** Connections of the amygdala with other early NFT regions: the entorhinal cortex, the
 5 hippocampus and the locus coeruleus. **D.** Preferential localization of NFT accumulation within the
 6 amygdala. **E.** Different functions associated with amygdala nuclei. AB=accessory basal nucleus,
 7 B=basal nucleus, BA=Brodmann Area, Ce=central nucleus, Co=cortical nuclei, ERC=entorhinal
 8 cortex, H=hippocampus, L=lateral nucleus, LC=locus coeruleus, M=medial nucleus,
 9 NFT=neurofibrillary tangles, TER=transentorhinal region. Note that different nomenclatures and
 10 groupings exist for the nuclei of the amygdala, where the following names can be used more or
 11 less synonymously: basal nucleus=basolateral nucleus, accessory basal nucleus=basomedial
 12 nucleus.

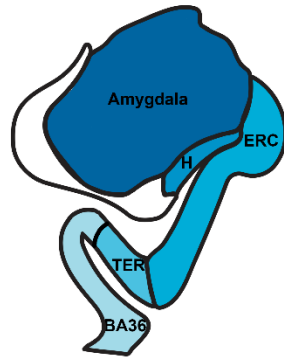
13
 14 **Figure 2 Schematic summary of preferred connectional relationships between amygdala,**
 15 **entorhinal cortex (ERC)* and hippocampus consistently established in animal studies and**
 16 **the density of early NFT pathology in AD patients. A.** (right) Schematic representation of the
 17 hippocampus indicating the longitudinal axis from anterior (yellow) to posterior (cyan); (middle)
 18 The same color code indicates the preferred connectivity of the ERC along the hippocampal long
 19 axis; (left) The same color code indicates the preferred connectivity of the amygdala along the
 20 hippocampal long axis. **B.** Schematic representation of preferred distribution of early stage NFT
 21 pathology in the amygdala, ERC, and hippocampal CA1/subiculum. The amygdala shows early
 22 NFT pathology in the inferior-medial domain (left), in the ERC early NFT pathology is mainly
 23 seen in anterolateral parts (middle), whereas in hippocampus (left) both anterior and posterior parts
 24 are indicated with a preferred density on both extents. Additionally, a density gradient along the
 25 transverse axis with high density in the border region between CA1 and subiculum has been
 26 indicated. **C.** Schematic representation of density gradients in reciprocal connectivity between
 27 amygdala and ERC. The densest connections are between the inferior part of the lateral, and
 28 basolateral nucleus, with the anterior-lateral portion of ERC (Magenta). The dashed line in the
 29 flattened representation of ERC/TER represents the fundus of the collateral & rhinal sulcus. *In
 30 the flattened representation of ERC, we included TER. TER, originally defined as a transition area

1 between ERC and the perirhinal cortex area 36, likely overlaps with part of the perirhinal cortex
2 area 35^{64,65}. Regarding its hippocampal connectivity, projections of area 35 in animals are largely
3 limited to the proximal subiculum and weakly to the adjacent distal CA1 at the posterior levels of
4 the hippocampus, i.e. similar to projections from the lateral ERC. AD=Alzheimer's disease;
5 CA=cornu ammonis; ERC=entorhinal cortex; NFT=neurofibrillary tangles; TER=transentorhinal
6 region.

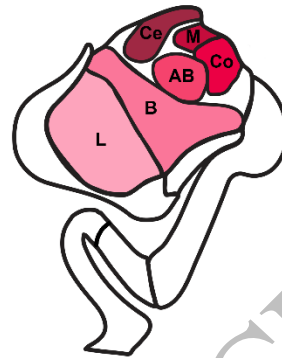
7

8 **Figure 3 Functional connectivity between the amygdala and hippocampus.** Displayed in
9 blue/green are the significant (FWE $p < .05$) clusters of a seed-to-voxel functional connectivity
10 analysis in young individuals between the amygdala and hippocampal voxels for each hemisphere,
11 respectively. The clusters are obtained by a one-sample T-test over all participants' connectivity
12 estimates. These estimates resulted from correlating residual time series between the amygdala
13 (seed) and hippocampal voxels on the participant level (non-directional functional connectivity).
14 Significant clusters are projected onto a 3D hippocampal mask (middle grey figures). Outer slices
15 display the clusters at the location of the stippled line in coronal view (1-6). The blue/green color
16 scheme indicates the height of T-values within significant clusters (significant with FWE $p < .05$
17 from $T > 7.4$). Note that results for the left and right hemispheres have been obtained by separate
18 analyses. More details and results can be found in Supplementary Material 1. For comparison, tau-
19 PET signal in MTL subregions from a recent study in patients with early Alzheimer's disease from
20 the Swedish BioFINDER study³² (Berron et al., 2021) are shown on representative slices side-by-
21 side to the functional connectivity results. The orange/yellow color scheme indicates the
22 Standardized Uptake Value Ratio (SUVR) values within significant clusters. FWE=family wise
23 error.
24

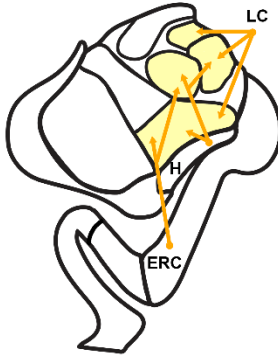
A MTL anatomy



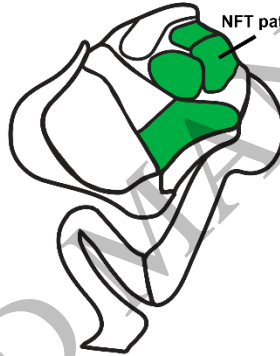B Amygdala nuclei



C Connections with early NFT regions



D Amygdala nuclei with early NFT deposition



E Functionality of amygdala nuclei

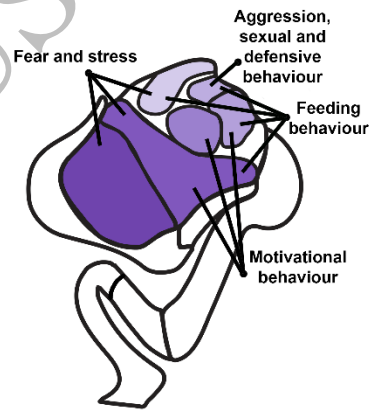


Figure 1
165x128 mm (x DPI)

1
2
3
4

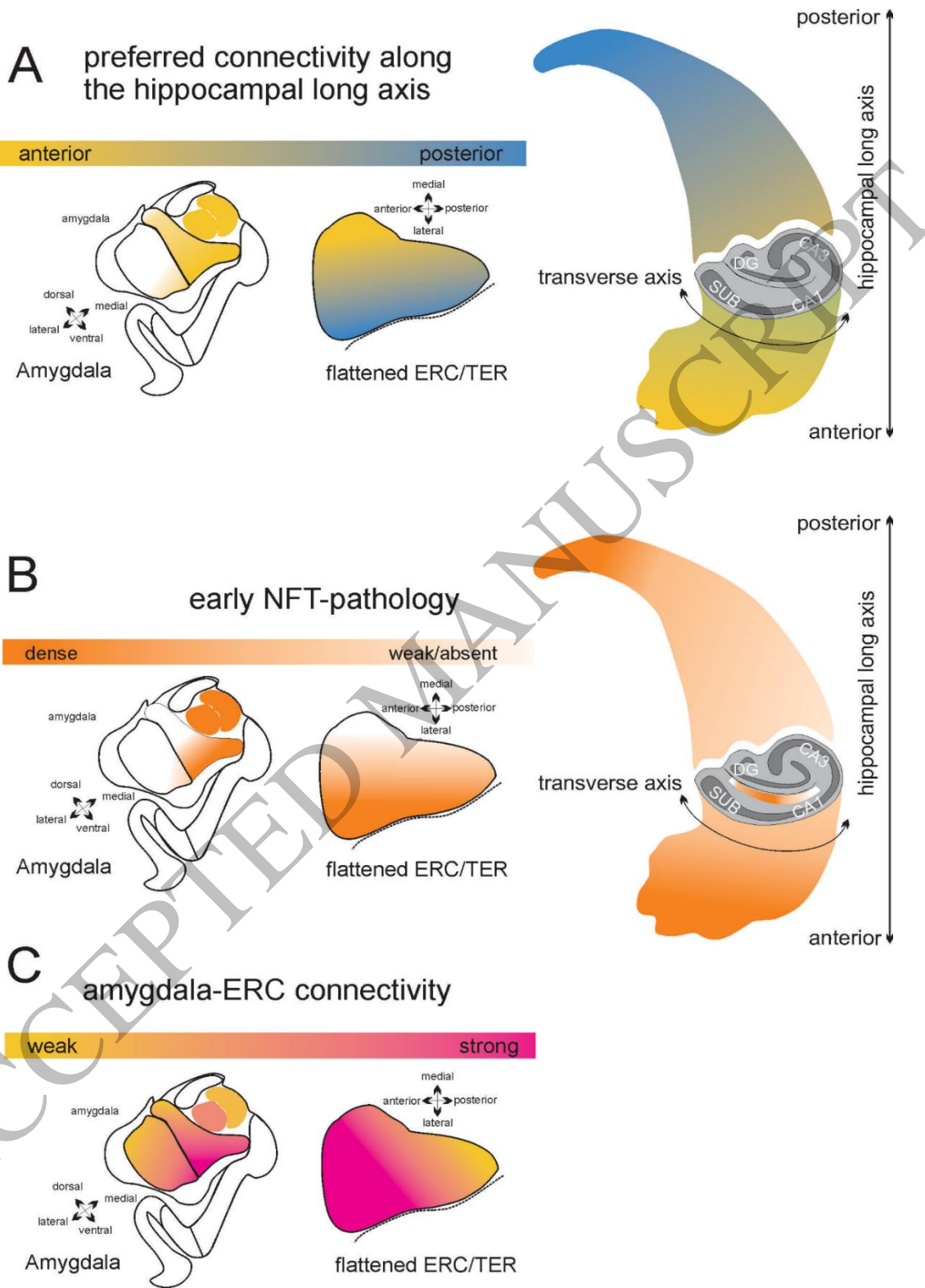
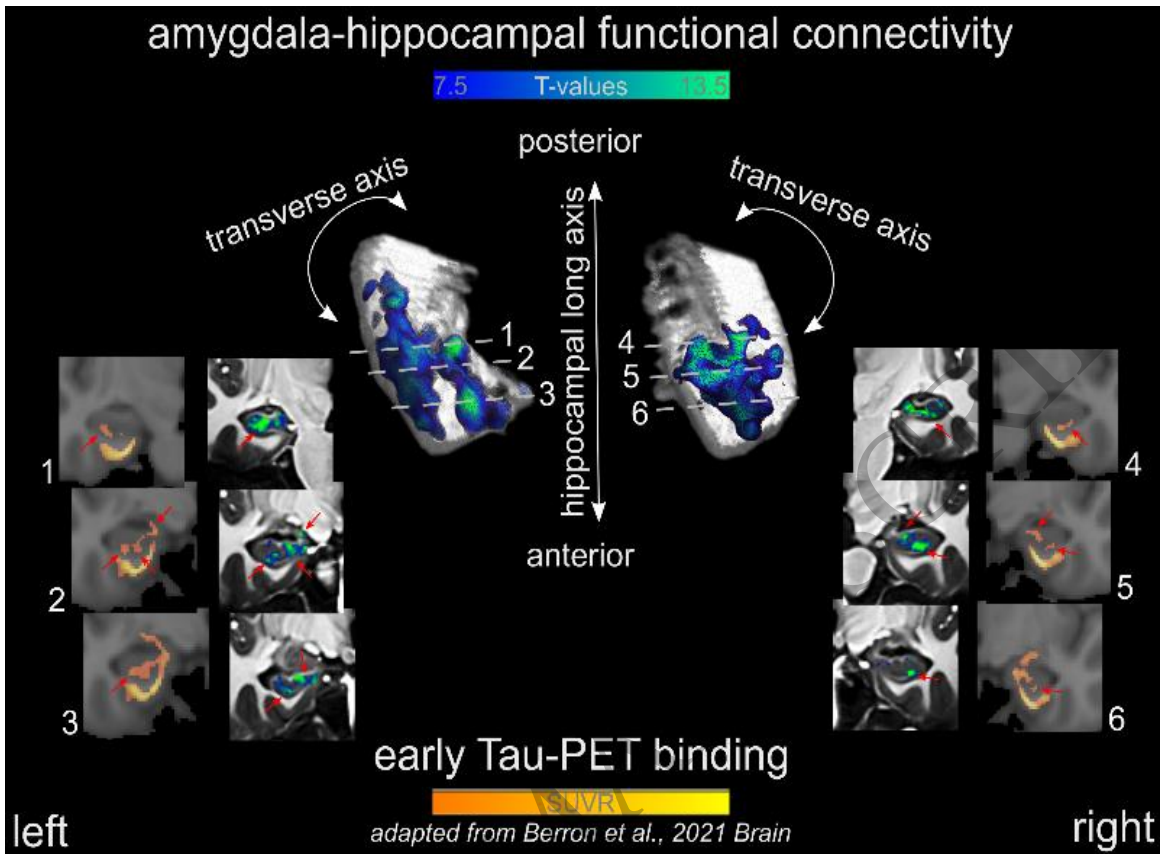


Figure 2
155x229 mm (x DPI)

1
2
3
4



1
2
3

Figure 3
92x64 mm (x DPI)

ACCEPTED